

AGE AND SEX DETERMINATION FROM THE MORPHOMETRIC CHARACTERISTICS OF THE 4TH COSTA ON MULTI-SLICE COMPUTERIZED TOMOGRAPHY

Mücahit Oruç¹, Osman Celbis¹, Semih Petekkaya², Gökhan Demirtas³, Bedirhan Sezer Öner⁴, İsmail Altın¹

1 – Inonu University Faculty of Medicine Department of Forensic Medicine Malatya, Turkey

2 – Canakkale Onsekiz Mart University Faculty of Medicine Department of Forensic Medicine, Canakkele, Turkey.

3- Health Ministry, Malatya Education and Research Hospital Radiology Clinic, Malatya, Turkey.

4- Amasya University Faculty of Medicine Department of Forensic Medicine, Amasya, Turkey.

Corresponding author: İsmail ALTIN, E-mail: drsmltn@gmail.com. Phone number: +905435496093

Submit Date 2020-05-08

Revise Date 2020-11-09

Accept Date 2020-11-13

ABSTRACT

Objectives: The determination of sex and estimation of age are parameters that help in the identification of individuals in all fields of forensic science. This study aimed to calculate standard measurements according to sex and age in morphometric analysis of the 4th costa using multi-slice computed tomography (MSCT). **Methodology:** Measurements were taken on MSCT images of patients aged 20-70 years, who had undergone CT imaging for various reasons. Using the morphometric characteristics of the 4th costa and junction with the spine on the thorax CT images, measurements were taken of the angulation of the right and left 4th costa, the distance between the sternum and the vertebra, the distance between the two costae, the distance between the two ends of the right and left 4th costa separately, and the depth of the two costae. Adding age and gender to these variables, 10 parameters were evaluated in total. Results: As a result of the analyses, the mean values of right costovertebral angle, sternum-vertebra distance, inter-costal distance, left and right costa lengths, and left costa depth were found to be statistically significant according to sex. In the differentiation of age groups, the right costovertebral angle, the sternum-vertebra distance, and the right and left costa lengths were found to be statistically significant. **Conclusion:** The results of this study of a Turkish population showed that the morphometric properties of the 4th costa show differences in the determination of age and sex. With the benefit of these differences, it is possible to differentiate males and females, and even age groups. As there are societal differences, standard morphometric values have to be determined so it will be necessary to conduct these studies more widely and obtain appropriate standard values for every population.

Keywords: identity determination, age, sex, fourth costa

INTRODUCTION:

All the characteristics that are effective in the recognition, definition and differentiation of a person from others are called “identity”. The revealing of these characteristics of a living or deceased person is the process of “identity determination” (Soysal and Çakalır, 1999). For various reasons, it may be

necessary to determine the identity of a living or deceased person. Identity determination of the living has become international in character with all the elements coming from an individual or societal case. Identification has become one of the most important subjects in forensic medicine (Koç and Can, 2011). All the procedures that are applied to the

living or the dead which are required in forensic medical examination start with the determination of identity, for which a series of methods are used, which can be listed as; identity documents, witnessed proof of identity, personal belongings, photographic comparison, facial reconstruction, forensic anthropology studies, teeth and bones, blood stains (**Aşirdizer M et al., 2005**).

In the process of identification, the determination of age and sex is made in particular. Since the beginning of the 20th century the results of systematic studies related to the ossification process of bones, and radiological anatomy atlases, widely used throughout the world, have been used to identify diseases related to skeletal development (**Ünlütürk and İşcan, 2013**). While determination of skeletal age was first used to determine growth disorders and estimate the adult height of children, in recent years forensic age determination has emerged as a very important area in the evaluation of the skeletal age of living persons (**Demirkıran et al., 2014**). In March 2000 the international and interdisciplinary Forensic Age Calculation Working Group was established in Berlin. This group produced guidelines to be used in age calculations in criminal, civil and asylum processes. To provide quality control of the age calculations, the participating centres were instructed to send physical examination findings and x-ray images of the cases several times a year for age calculations to be made (**Association for Forensic Age Diagnostics. (AGFAD)**).

Sex determination from skeletal remains is extremely important for any forensic investigation. The determination of sex from a human skeleton is made with non-metric measurements by forensic medicine specialists, anthropologists and anatomists. In recent years, sex differentiation has been able to be made on different bones. All the bones of the body are used, primarily the long bones, skull bones and pelvic bones (**Ünlütürk and**

İşcan, 2013, Hussein et al., 2016).

The morphometric standards determined for gender differences in the skeleton may vary according to the relevant population. Genetic, environmental, and climate differences can change the phenotype of a population. Therefore, the morphometric standards determined for a population cannot be applied universally. As a general rule, if standards have been determined for a certain population, they can only be applied to that population (**Niggemann et al., 2012, Sweilum et al., 2017**).

The estimation of bone age and sex is an important part of forensic anthropology. Costa morphometry is of great importance in anthropological studies, and this can be examined with radiological methods or macroscopic examination. In the age determination of the dead, macroscopic methods, in particular, are used. Good results have been obtained in studies made using the pubis joint, the ileum, right 4th rib, and forearm bones (**Bass, 2005**). In age and sex determination of the living, useful results have been obtained with radiological methods rather than macroscopic, and especially with multi-slice computed tomography (MSCT) (**Nougarolis et al., 2017**). Significant advantages of this are the ability to prevent artefacts in radiological studies, the ability to obtain 3-dimensional imaging with developing technology and to take repeated measurements from the stored digital data (**Ekizoğlu et al., 2017**).

In human identification, the physical characteristics of sex, age, height, weight, hair, skin, eye colour, fingerprints, bones and teeth are taken into consideration. Of these, age and sex are of great importance for forensic medicine identity determination (**İşcan et al., 1989**).

The present study aimed to determine 1) standardized angulation values between the 4th costa and the corresponding thoracic vertebra, 2) the distance between the sternum, costa and vertebra according to age and sex using MSCT.

MATERIAL & METHOD

A. Equipment and Method:

The study included subjects who had presented at the Radiology Department of İnönü University Turgut Özal Medical Centre and underwent thorax tomography. The study was conducted between 2014-2015. Patients in the age range of 20-70 years were selected at random irrespective of gender. The images were excluded from the study if the patient had congenital or acquired thorax or vertebra deformity, chest trauma, a history of chest disease or metabolic disease, chronic obstructive pulmonary disease (COPD) which could lead to thorax deformity, asthma or obesity.

A total of 133 males and 126 females were identified within a one-year period who met the study criteria. As a result of power analysis, two groups were formed, including an equal number of males and females. The thorax image measurements were taken using an MSCT unit (Somatom Emotion 16-slice, Siemens, Germany) (Figure-1). The measurements were made in a double-blinded manner by a Forensic Medicine specialist and a Radiology specialist. The morphometric parameters were the measurements of the angle made by the right and left 4th costa with the vertebra at the same level, the distance between the vertebra and the sternum, the distance between the two 4th costae, the length of each 4th costa separately, and the deepest length of each 4th costa (Mc Cornick, 1980, Darwish et al., 2017).

B. Morphometric Parameters Measured in the Study

In the measurements, the midline was

determined by drawing a vertical line from the sternum to the 4th thoracic vertebra of the subject parallel to the ground. By determining the 4th costa forming the joint with the transverse process of the vertebra, the angle made with this line was measured (Figure-2, Figure-3). The measurement was made on both left and right sides. Then the distance between the sternum and the vertebra corpus was measured (Figure-4). The costa diameter was measured taking into consideration the deepest sections of both costae. The distance between the costovertebral joint and the sternovertebral joint was measured separately for each costa (Figure-4). Then the distance of the deepest section of the costae to be 90° from these lengths was measured separately (Figure-5, Figure-6). All the measurements were taken by two researchers at different times.

Approval for the study was granted by the Ethics Committee of the relevant department of the university

C. Statistical Analysis

It was calculated in the power analysis that for a mean angle difference of 2.3° in the 4th costa according to sex when $\alpha=0.05$ and power = 0.80, it was necessary to have 126 subjects in each group. In the comparison of the morphometric measurements of the 4th costa according to sex, the Student's t-test was used. In the comparison of the morphometric measurements of the 4th costa according to age groups, the Anova test was applied to parameters showing normal distribution and the Kruskal Wallis test for parameters not showing normal distribution.

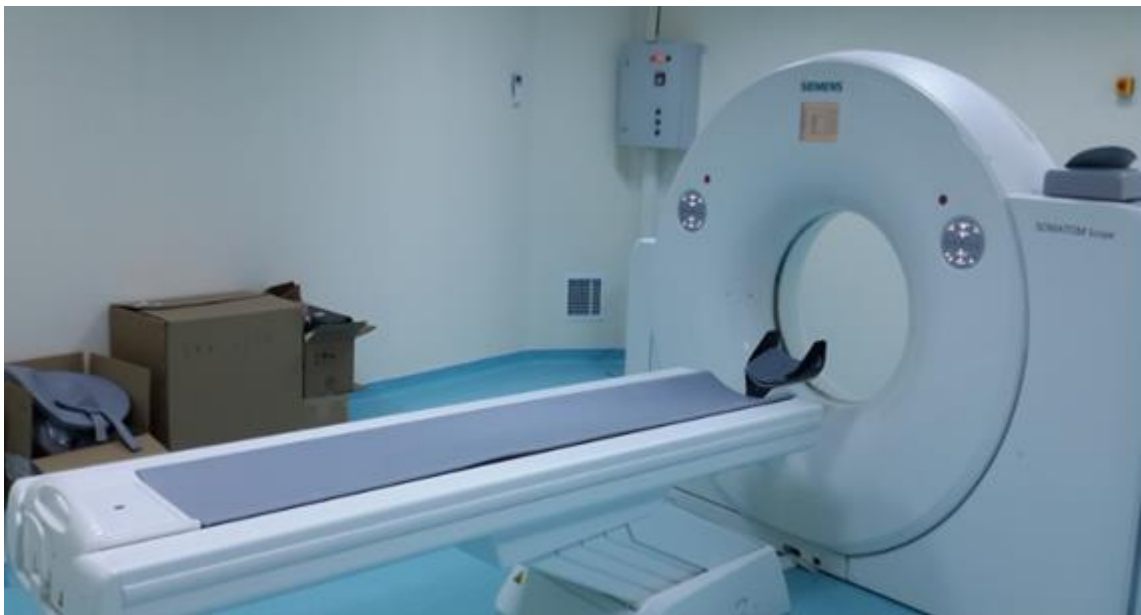

Figure (1): Siemens SomatomEmotion 16 Slice Multi-slice Computed Tomography

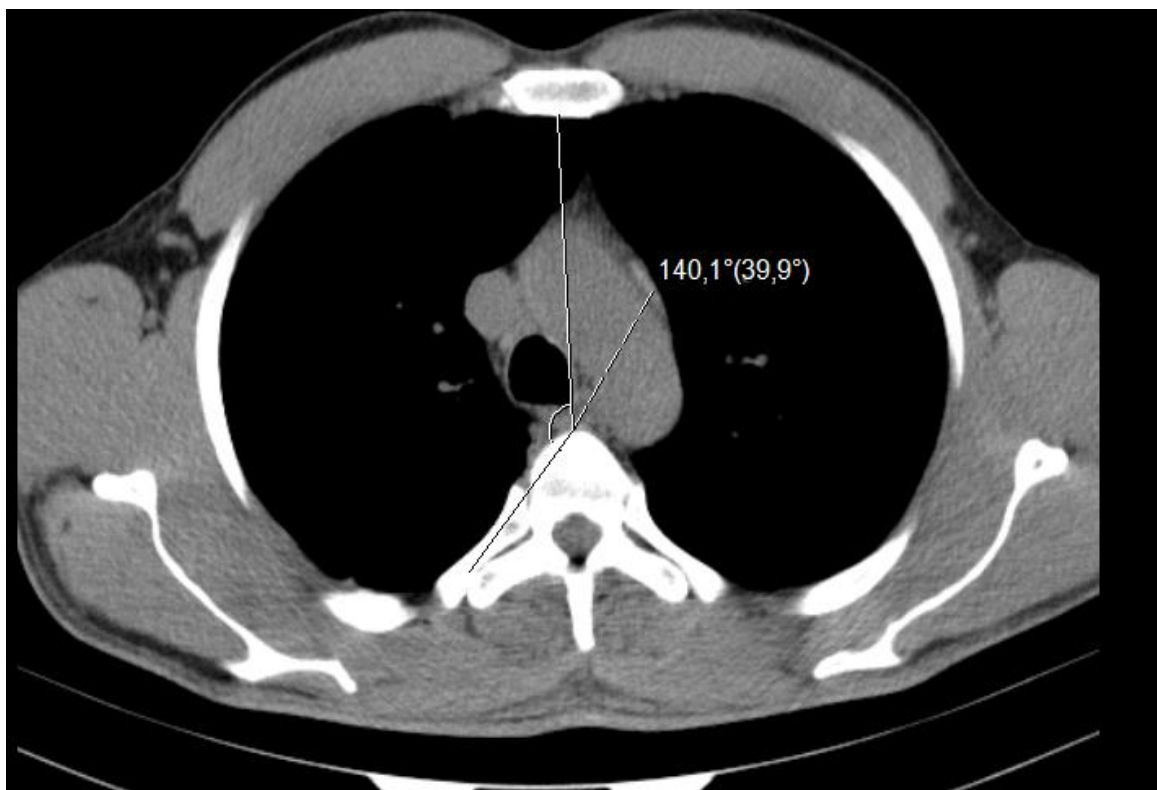


Figure (2): Right-side 4th costovertebral angle measurement

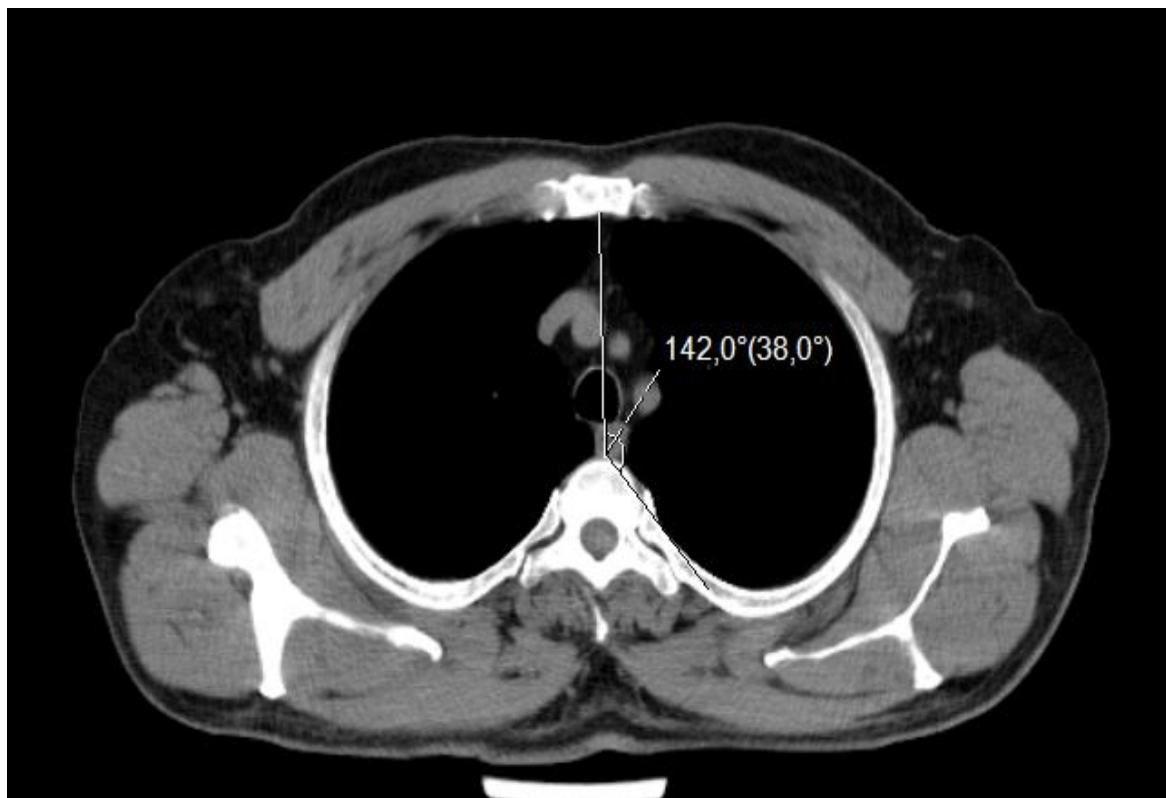


Figure (3): Left-side 4th costovertebral angle measurement

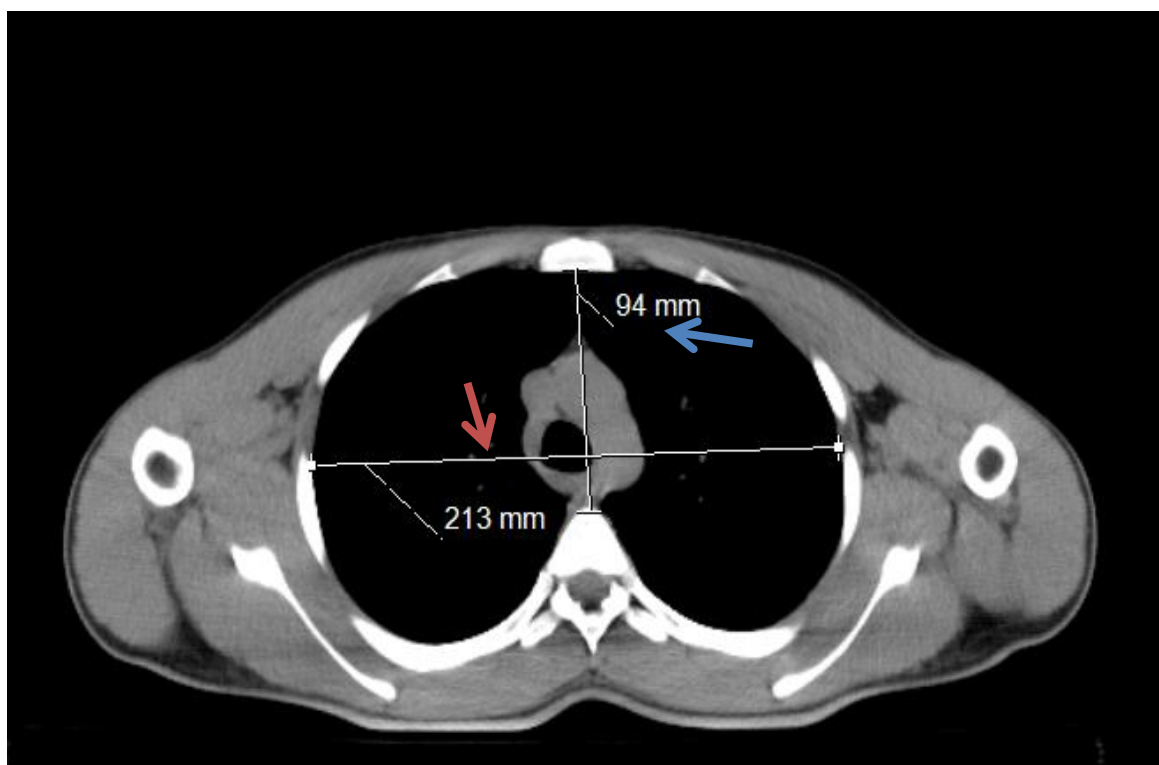


Figure (4): Measurement of the distance between the sternum - vertebra and 4th costa
The measurement of the distance between the two costae is shown with the red arrow
The measurement made between the vertebra and the sternum is shown with the blue arrow

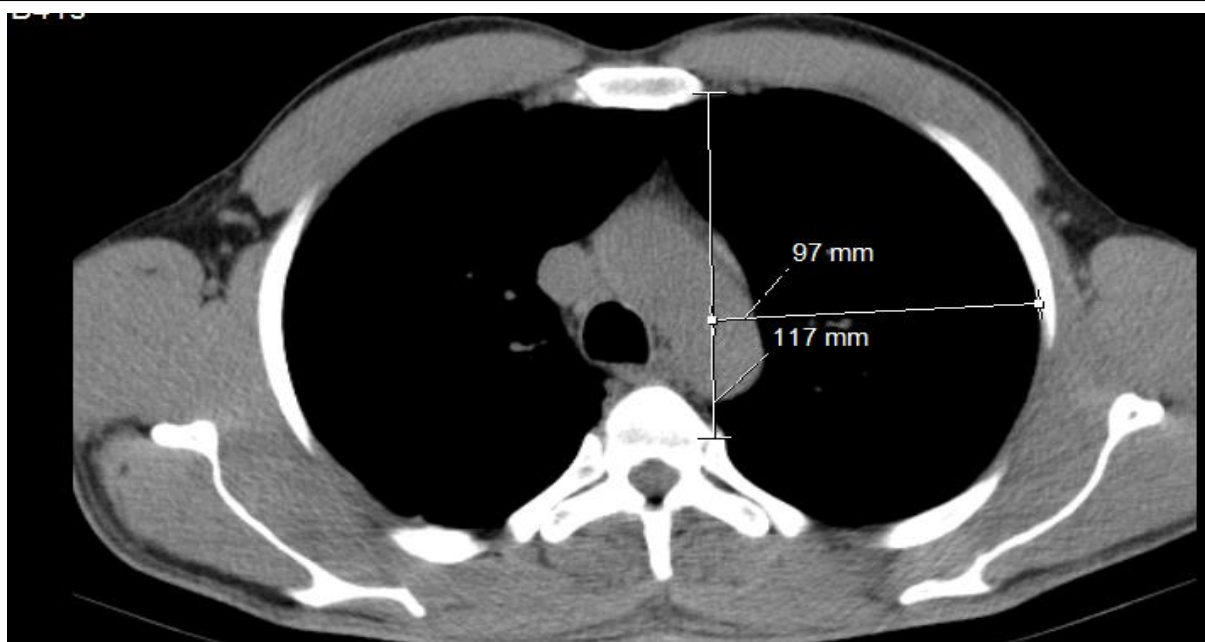


Figure (5): Measurement of the length and depth of the left-side 4th costa

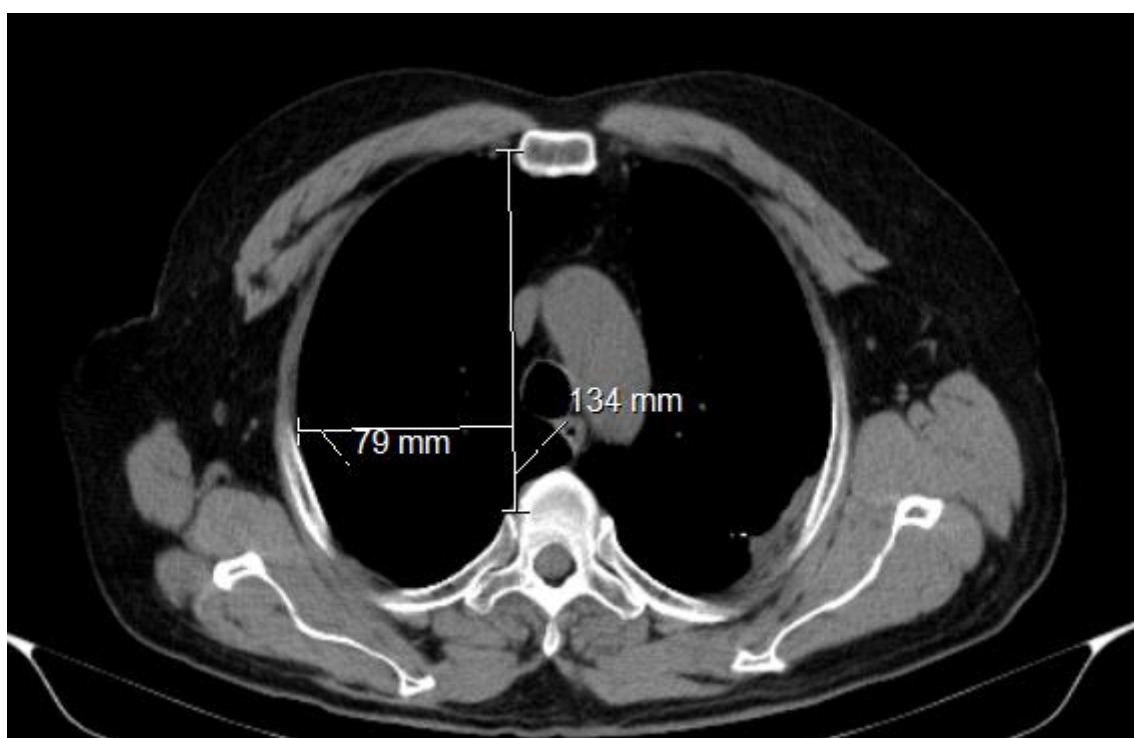


Figure (6): Measurement of the length and depth of the right-side 4th costa

RESULTS

The mean age of the cases was calculated as 48.65 ± 14.80 years for males and 45.90 ± 13.40 years for females. The mean left costovertebral angle was calculated as $138.76^\circ \pm 5.89^\circ$ in males and $139.41^\circ \pm 6.13^\circ$ in females, with no statistically significant difference determined (t-test: $p > 0.05$). The mean right

costovertebral angle was calculated as $137.54^\circ \pm 5.62^\circ$ in males and $139.05^\circ \pm 5.35^\circ$ in females, with a statistically significant difference (t-test: $p < 0.05$) (Table-1).

The distance between the sternum and the vertebra was measured as 89.67 ± 15.99 mm in males and 78.50 ± 14.38 mm in females, with the difference determined as statistically

significant in the t-test ($p < 0.05$). The distance between the two costae from the deepest point was measured as 219.95 ± 19.36 mm in males and 198.77 ± 20.5 mm in females, with the difference determined as statistically significant in the t-test ($p < 0.05$) (Table-1).

The length of the left costa measured between the two ends was 115.02 ± 62.79 mm in males and 97.18 ± 16.34 mm in females with the difference determined as statistically significant in the t-test ($p < 0.05$). The length of the right costa measured between the two ends was

108.16 ± 18.15 mm in males and 96.54 ± 17.08 mm in females with the difference determined as statistically significant in the t-test ($p < 0.05$) (Table-1).

The depth of the left costa was measured as mean 90.82 ± 10.84 mm in males and 82.34 ± 9.10 mm in females, with the difference determined as statistically significant in the t-test ($p < 0.05$). The depth of the right costa was measured as mean 90.61 ± 10.71 mm in males and 81.62 ± 10.15 mm in females, with the difference determined as statistically significant in the t-test ($p < 0.05$) (Table-1).

Table (1): Comparison of the morphometric measurements of the costae according to sex

	Male	Female	t	p
	Mean \pm SD	Mean \pm SD		
Age	48.65 \pm 14.80	45.90 \pm 13.40	1.56	0.119
Left costovertebral angle	138.76 \pm 5.89	139.41 \pm 6.13	-0.87	0.385
Right costovertebral angle	137.54 \pm 5.62	139.05 \pm 5.35	-2.20	0.028
Sternum-vertebra distance	89.67 \pm 15.99	78.50 \pm 14.38	5.85	0.000
Distance between costae	219.95 \pm 19.36	198.77 \pm 20.5	8.46	0.000
Left costa length	115.02 \pm 62.79	97.18 \pm 16.34	3.08	0.000
Right costa length	108.16 \pm 18.15	96.54 \pm 17.08	5.25	0.000
Left costa depth	90.82 \pm 10.84	82.34 \pm 9.10	6.75	0.000
Right costa depth	90.61 \pm 10.71	81.62 \pm 10.15	6.86	0.000

* As the data conformed to the normal distribution, the t-test was applied and a value of $p < 0.05$ was accepted as statistically significant

Comparison of the morphometric measurements of the costae according to age groups

The mean right costovertebral angle was calculated as $138.52 \pm 4.70^\circ$ in the 20-30 years age group, $137.83 \pm 4.26^\circ$ in the 31-40 years age group, $136.35 \pm 5.18^\circ$ in the 41-50 years age group, $138.51 \pm 6.24^\circ$ in the 51-60 years age group, and $139.62 \pm 6.12^\circ$ in the 61-70 years group. As a result of the Anova test, the differences were found to be statistically significant ($p < 0.05$) (Table-2).

The sternum-vertebra distance was measured as 76.73 ± 15.38 mm in the 20-30 years age group, 77.67 ± 11.90 mm in the 31-40 years age group, 83.45 ± 15.10 mm in the 41-50 years age group, 89.40 ± 14.22 mm in the 51-60 years age group, and 88.96 ± 18.51 mm in the 61-70

years group. As a result of the Anova test, the differences were found to be statistically significant ($p < 0.05$) (Table-2).

The distance between the two 4th costae was measured as 211.94 ± 22.37 mm in the 20-30 years age group, 212.52 ± 22.33 mm in the 31-40 years age group, 207.09 ± 26.02 mm in the 41-50 years age group, 206.44 ± 25.34 mm in the 51-60 years age group, and 210.25 ± 17.70 mm in the 61-70 years group. As a result of the Anova test, no statistically significant difference was determined ($p > 0.05$) (Table-2).

The length of the right 4th costa measured between the two ends was 93.59 ± 17.25 mm in the 20-30 years age group, 95.72 ± 13.40 mm in the 31-40 years age group, 101.55 ± 19.82 mm in the 41-50 years age group, 108.83 ± 15.86 mm in the

51-60 years age group, and 107.29±20.33 mm in the 61-70 years group. As a result of the Anova test, the differences were found to be statistically significant ($p<0.05$) (Table-2).

The depth of the left 4th costa was measured as 86.68±11.77mm in the 20-30 years age group, 88.44±10.06 mm in the

31-40 years age group, 85.28±12.31mm in the 41-50 years age group, 87.15±10.16mm in the 51-60 years age group, and 85.87±10.56 mm in the 61-70 years group. As a result of the Anova test, no statistically significant difference was determined ($p>0.05$) (Table-2).

Table (2): Comparison of the morphometric measurements of the 4th costae according to age groups (parameters showing normal distribution)

	20-30 years	31-40 years	41-50 years	51-60 years	61-70 years	F	p
	Mean±SD n	Mean±SD n	Mean±SD n	Mean±SD n	Mean±SD n		
Right costovertebral angle	138.52±4.7 0	137.83±4.2 6	136.35±5.1 8	138.51±6.2 4	139.62±6.1 2	2.65	0.03 4
Sternum-Vertebra distance	76.73±15.3 8	77.67±11.9 0	83.45±15.1 0	89.40±14.2 2	88.96±18.5 1	7.44	0.00 0
Distance between costae	211.94±22. 37	212.52±22. 33	207.09±26. 02	206.44±25. 34	210.25±17. 70	0.72 1	0.57 8
Right costa length	93.59±17.2 5	95.72±13.4 0	101.55±19. 82	108.83±15. 86	107.29±20. 33	7.00 1	0.00 0
Left costa depth	86.68±11.7 7	88.44±10.0 6	85.28±12.3 1	87.15±10.1 6	85.87±10.5 6	0.64 1	0.63 4

* As the data conformed to the normal distribution, the Anova test was applied and a value of $p<0.05$ was accepted as statistically significant

The mean left costovertebral angle was calculated as 122.96 ° in the 20-30 years age group, 125.44° in the 31-40 years age group, 123.56° in the 41-50 years age group, 130.01° in the 51-60 years age group, and 141.31° in the 61-70 years group. As a result of the Kruskal Wallis test, no statistically significant difference was determined ($p>0.05$) (Table-3).

The mean length of the left 4th costa measured between the two ends was 90.81mm in the 20-30 years age group, 99.28mm in the 31-40 years age group, 132.27mm in the 41-50 years age group,

150.71mm in the 51-60 years age group, and 144.62mm in the 61-70 years group. As a result of the Kruskal Wallis test, the differences were found to be statistically significant ($p<0.05$) (Table-3).

The depth of the right 4th costa was measured as mean 131.26 mm in the 20-30 years age group, 144.70 mm in the 31-40 years age group, 121.49mm in the 41-50 years age group, 123.18mm in the 51-60 years age group, and 120.66mm in the 61-70 years group. As a result of the Kruskal Wallis test, no statistically significant difference was determined ($p>0.05$) (Table-3).

Table 3: Comparison of the morphometric measurements of the 4th costae according to age groups (parameters not showing normal distribution)

	20-30 years	31-40 years	41-50 years	51-60 years	61-70 years	X ²	p
	Mean ±Sd	Mean± Sd	Mean± Sd	Mean± Sd	Mean± Sd		
Left costovertebral angle	122.96	125.44	123.56	130.01	141.31	2.45	0.65
Left costa length	90.81	99.28	132.27	150.71	144.62	25.20	0.000
Right costa depth	131.26	144.70	121.49	123.18	120.66	3.93	0.415

* As the data did not conform to the normal distribution, the Kruskal Wallis test was applied and a value of $p < 0.05$ was accepted as statistically significant

DISCUSSION

There is a current need for identification in wars, natural disasters, refugee deaths, deaths in massive accidents, and because of the problems encountered in the international judicial system during the proceedings of crimes against humanity. Since the judicial authorities ask anthropologists and forensic medicine experts for help, the number of identifications is increasing every year together with the development of biological profiles. In the past, manual studies were performed on wet and dry bones from skeletal remains using macroscopic examination methods for age and sex determination. In this century, the use of radiological examination methods in bone examination for age determination, especially in living cases, is demanded by the judicial authorities as damage is minimal. Recent literature in particular has shown that the CT scan is an effective method in macroscopic bone studies (Niggemann et al., 2011). Although there are studies in literature on age and sex determination using CT investigations on various bone groups, the present study is the first to be based on the angulation of the 4th costa with respect to the vertebrae.

McCormick et al. investigated more than 1100 chest plate roentgenograms and reported, that the width of the 4th costa is more sexually dimorphic than the 2nd, 3rd and 5th costae (McCormick, 1980). In 2003, Kocak et al. also confirmed that the sexual dimorphism can be evaluated using the right 4th costa (Kocak et al., 2003).

Another study conducted in Egypt revealed that osteometric analysis of the width of the 4th costa is a precise method of sex determination from skeletal remains (Darwish et al., 2017). In a study conducted by Iscan et al., in which the measurements were made on dry bones, it was stated that the right 4th costa shows age-related changes and it can be used in sex determination with great reliability (İşcan et al., 1984). In a study by Gangal et al. in which they investigated the role of the sternal end of the 4th costae in the sex determination of 94 dead bodies at autopsy, it was demonstrated that there is a clear difference between males and females in respect of the anterior to posterior width of the 4th costae and it can be used in sex determination (Gangal et al., 2012). The accuracy of sex determination has been shown to be high in the analyses of cases aged 40 to 75 years and the accuracy decreases when the cases are younger than 15 years. In addition, the anterior to posterior width of the right and left costae has been stated to be the most reliable measurement in sex determination (Gillet et al., 2020). In line with the literature, the results of this study revealed the importance of the 4th costae in determining age and sex. In the current study, when the distances between the right and left 4th costae were compared, there were seen to be significant differences between the age groups of younger than 40 years and older than 50 years. The mean costovertebral angle of the right 4th costae was found to be significantly higher in

females than in males. This is the first study in the literature to have demonstrated this. There was also a statistical difference between the 41 – 50 years and 61 – 70 years age groups, with the mean distance between the sternum and vertebrae measured at a greater value in males than in females. This will be beneficial in studies in which radiological examination methods are used, especially for sex determination.

One of the earliest studies that considered the costa features and used CT in age and sex determination evaluated the sternal end features of the first costa of 160 subjects aged between 15 and 30 years. That study revealed that the sternal end features of the first costa made it possible to determine the age of living or dead young subjects (age < 30 years) (Moskovitch et al., 2010). When the age groups were compared in the current study, there were statistically significant differences between the age groups of 20 – 30 and 51 – 60 and, 61 – 70, and between 31 – 40 and 51 – 60 years, and 61 – 70 years. Statistically significant results were obtained when the right 4th costovertebral angle, the distance between the sternum and vertebra, and the lengths of the right and left 4th costae were measured. It was determined that the right 4th costovertebral angle decreases with ageing up to the age group of 41 – 50 years and then increases again with further ageing, and other parameters were found to increase in parallel with age. The endocrinological and osteological changes such as menopause, andropause and osteoporosis that individuals develop with ageing are known to have effects on the above-mentioned parameters. On the basis of the data from the present study, the differences between the sexes, similar to data from previous studies, can be considered to be linked to endocrine and biomechanical differences. It is also thought that the difference between the sexes that was observed only in the right costovertebral angle measurements, especially when the differences between measurements of the left and right 4th

costovertebral angle were considered, is related to the anatomic structure rather than the factors mentioned above, and the localisation of the heart and other major vascular structures on the left side of the thorax explains the lack of statistical difference.

A study of 340 subjects used the data from measurements of the 4th costa and sternum in sex determination and revealed that the best data for sex determination was obtained from MSCT scans of the sternal area and the width of the 4th costa. The use of the width of the left 4th costa for sex determination was also suggested because the width measurements of the left 4th costa were more significant than the width measurements of the right 4th costa. It was reported that cut-off values of 5600 mm² for the sternal area and 16 mm for width of the 4th costa can be used for sex determination (Ramadan et al., 2010). The data obtained in the study were compatible with the literature. In the current study, the mean distance between both costae at the deepest level was determined to be greater in males than females. The measurements for the evaluation of the distance between the costosternal and costovertebral parts of both right and left costae on a straight line revealed that mean distance was greater in males than in females and the difference was found to be significant in respect of sexual dimorphism.

CONCLUSION

The determination of age and sex from the living, the deceased, and skeletal remains is of the greatest importance in identity determination by anatomists, anthropologists and forensic medicine specialists. The costae are bones that are often used by researchers in sex determination. Genetic, physical and nutritional conditions, congenital anomalies, endocrinological disorders, osteoporotic changes, environmental and climate differences change the phenotype of a population. The morphometric standards determined for age and sex

differences vary according to the related population. Therefore, there is a need for new studies of societies at certain intervals, and the advantages and superiorities of computed tomography in these studies have been shown compared to other methods. Computed tomography previously taken for any reason will be useful in clarifying identity determination.

It was determined in this study that the right costovertebral angle, the distance between the sternum and the vertebra, the distance between the ribs, the right and left costal distance, and the right and left costal depth could be used for sex determination. It was also determined that the right costovertebral angle, the distance between the sternum and the vertebra, the right costal distance and the left costal distance could be used for age determination.

In this study of a Turkish population, differences were determined in the 4th costae morphometric characteristics in age and sex determination. The results showed that with the benefit of these differences, male and female differentiation can be made and even age groups can be determined. As it is necessary to determine morphometric standard values because of societal differences, it can be considered necessary for these studies to become more widespread and for appropriate standard values to be obtained for every population.

REFERENCES

- Association for Forensic Age Diagnostics. (AGFAD)** http://agfad.uni-muenster.de/agfad_start.html. (last accessed on 18 October 2019).
- Aşirdizer M., Yavuz MS., Zeyfeoğlu Y. (2005):** Adli Tıp Ders Notları. Manisa: Celal Bayar Üniversitesi; 117-37.
- Ateşoğlu S., (2012):** Sternumun Morfolojik Özellikleri Ve Cinsiyet Farklılıklarının Multi-Slice BT ile Değerlendirilmesi, Harran Üniversitesi Sağlık Bilimleri Enstitüsü Anatomi Anabilim Dalı Yüksek Lisans Tezi.
- Bass WM. (2005):** Missouri Archaeological Society. Human osteology: a laboratory and field manual, 5th edn. Springfield, MO: Missouri Archaeological Society.
- Darwish RT., Abdel-Aziz MH., El Nekiedy AM., Sobh ZK. (2017):** Sex Determination From Chest Measurements In A Sample Of Egyptian Adults Using Multislice Computed Tomography. *J Forensic Leg Med*; 52:154-8.
- Demirkıran DS., Çelikel A., Zeren C., Arslan MM. (2014):** Methods For Age Estimation. *Dicle Medical Journal*; 41(1): 238-43.
- Ekizoğlu O., Hocaoğlu E., İnci E. (2017):** Use of Frontal Sinus Morphometric Analysis by Computerized Tomography in Sex Determination. *Adli Tıp Bülteni*; 22 (2): 91-6.
- Gangal R., Haroon A., Yadav M., Chavada VK. (2012):** Sex Determination From Sternal End Of 4th Rib In Western U.P. Population: An Autopsy Study. *J Indian Forensic Sci*; 34:332-5
- Gillet C., Costa-Mendes L., Rérolle C., Telmon N., Maret D., Savall F. (2020):** Sex Estimation In The Cranium And Mandible: A Multislice Computed Tomography (MSCT) Study Using Anthropometric And Geometric Morphometry Methods. *Int J Legal Med*;134(2):823-832.
- Hussein, R., Shokry, D., Ismail, M., Abd-Elsatar, M., Ibrahim, S. (2016):** Sex Identification From Radiologic Anthropometry Of Sacral And Fifth Lumbar Vertebral Measurements. *The Egyptian Journal of Forensic Sciences and Applied Toxicology*, 16(2), 117-126.
- İşcan MY., Loth BA., Wright RK. (1984):** Age Estimation From Rib By Phase Analysis: White Males *J Forensic Sci*; 29:1094-104.
- İşcan MY., Loth SR., Schuerman EH. (1989):** Assessment of intercostal Variation on the estimation of age from the sternal end of the rib, *Am J*

- Phys Antropol; 78:245.
- Karakaş MH., Celbis O., Harma A., Aliciöglu B. (2011):** Total Body Height Estimation Using Sacrum Height İn Anatolian Caucasians: Multidetector Computed Tomography-Based Virtual Anthropometry. *Skeletal Radiol*; 40:623–30.
- Kocak A., Aktas EO., Erturk S., Aktas S., Yemiscigil A. (2003):** Sex Determination From The Sternal End Of The Rib By Osteometric Analysis. *Leg Med*; 5:100–4.
- Koç S., Can M. (2011):** Birinci Basamakta Adli Tıp. 2th edition, İstanbul: İstanbul Tabip Odası; 18-38
- Mc Cornick WF. (1980):** Mineralization Of The Costal Cartilages As An Indicator Of Age: Preliminary Observations *J Forensic Sci*; 25:736-41
- Moskovitch G., Dedouit F., Braga J., Rougé D., Rousseau H., Telmon NJ. (2010):** Multislice Computed Tomography Of The First Rib: A Useful Technique For Bone Age Assessment. *Forensic Sci Int* 55(4):865–70.
- Niggemann P., Wildberger JE., Günther RW., Mahnken AH. (2005):** Multislice Computed Tomography Of The Sternum: Which İmage Reconstruction Do We Need? *Radiat Med*; 23(7): 491-6.
- Nougarolis F., Mokrane FZ., Sans N., Rousseau H., Dedouit F., Telmon N. (2017):** Bone Age Estimation Based On Multislice Computed Tomography Study Of The Scapula. *Int J Legal Med*; 131(2):547–58.
- Ramadan SU., Türkmen N., Dolgun NA., Gökharman D., Menezes RG., Kacar M., Koşar U. (2010):** Sex Determination From Measurements Of The Sternum And Fourth Rib Using Multislice Computed Tomography Of The Chest. *Forensic Sci Int*; 197:120.e1-120.e5.
- Soysal Z., Çakalır C. (1999):** Adli Olaylarda Kimlik Belirlemesi. *Adli Tıp Cilt 1. İstanbul: İ.Ü. Tıp Fakültesi Yayınları*; 73-92
- Sweilum, O., Galal, H., Habib, R. (2017):** Determination Of Sex From The Sternum And Fourth Rib Measurements (A Cross-Sectional Study (Using Thoracic Computed Tomography (Ct) Images. *The Egyptian Journal of Forensic Sciences and Applied Toxicology*, 17(2), 27-38.
- Ünlütürk Ö., İşcan MY. (2013):** Tanınabilir Vertebralardan Cinsiyet Tayini. *Adli Tıp Bülteni*;18(1):4-13.

تحديد العمر والجنس من الخصائص المورفومترية لكوستا الرابعة باستخدام الأشعة المقطعية متعددة المقاطع

Mücahit Oruç¹, Osman Celbis¹, Semih Petekkaya², Gökhan Demirtas³, Bedirhan Sezer Öner⁴, İsmail Altın¹

1 – Inonu University Faculty of Medicine Department of Forensic Medicine Malatya, Turkey

2 – Canakkale Onsekiz Mart University Faculty of Medicine Department of Forensic Medicine, Canakkele, Turkey.

3- Health Ministry, Malatya Education and Research Hospital Radiology Clinic, Malatya, Turkey.

4- Amasya University Faculty of Medicine Department of Forensic Medicine, Amasya, Turkey.

الهدف:

يعد تحديد الجنس وتقدير العمر في جميع مجالات علوم الطب الشرعي أحد المعلومات المستخدمة في تحديد هوية الشخص. في دراستنا ، سعينا إلى حساب القياسات القياسية وفقاً للجنس والعمر من خلال إجراء تحليل مورفومتري للتكساس الرابع باستخدام التصوير المقطعي المحوسب متعدد الشرائح (MDCT).
المواد والطرق :

تم أخذ التصوير المقطعي المحوسب للمرضى الذين تتراوح أعمارهم بين 20 و 70 لأسباب مختلفة عن طريق أخذ قياسات على صور الأشعة المقطعية متعددة الشرائح على الصور المقطعية للصدر باستخدام الخصائص المورفومترية للكوستا والحبل الشوكي الذي تتضمن إليه. تم فتح الكوسترا الرابعة اليمنى واليسرى ، والمسافة بين فقرة القص ، والمسافة بين الكوستا ، والمسافة بين طرفي كوستا الرابع الأيمن والأيسر وعمق كلتا كوستا وتم تقييم ما مجموعه 10 معلمات من خلال إضافة العمر والجنس إلى هذه المتغيرات.

النتائج:

نتيجة التحليل ؛ كانت متوسطات الزوايا اليمنى في العمود الفقري ، والمسافة بين فقرة القص ، والمسافة بين الكوستا ، والمسافة إلى الكوستا اليسرى ، والمسافة إلى الكوستا اليمنى ، وعمق الكوستا اليسرى ذات دلالة إحصائية. تم العثور على زاوية العمود الفقري الأيمن ، والمسافة بين فقرة القص والمسافة اليمنى البعيدة والمسافة الضلعية اليسرى ذات دلالة إحصائية بين الفئات العمرية.

نتيجة:

في دراستنا عن السكان الأتراك ، قررنا أن الخصائص المورفومترية للكوستا الرابعة اختلفت في تحديد العمر والجنس. من خلال الاستفادة من هذه الاختلافات ، سيكون من الممكن التمييز بين الرجال والنساء وحتى الفئات العمرية. نظراً لأنه يجب تحديد القيم القياسية المورفومترية بسبب الاختلافات الاجتماعية ، نعتقد أن هذه الدراسات يجب أن تصبح واسعة الانتشار ويجب الحصول على القيم المعيارية المناسبة لكل مجتمع.
الكلمة الرئيسية: التعريف ، العمر ، الجنس ، الرابع. كوستا