

CARDIOPROTECTIVE EFFECTS OF MORINGA OLEIFERA EXTRACT ON BIOCHEMICAL, INFLAMMATORY, HISTOLOGICAL, AND ULTRASTRUCTURAL CHANGES IN NANDROLONE DECANOATE INDUCED CARDIOTOXICITY IN MALE ADULT ALBINO RATS

Hend R. Mousa¹, Abeer A. Eldeeb², Ali M. Ali¹

¹Departement of Anatomy and Embryology, ²Departement of Pharmacology, Benha Faculty of Medicine, Benha University, Egypt

Corresponding author: **Hend R. Mousa.**

Department of anatomy and embryology, Faculty of Medicine, Benha University, Benha, Egypt.

Mobile: 01222898035

Email: drhendragab@yahoo.com

ABSTRACT

Background: Nandrolone-decanoate (ND); is an anabolic steroid. Its toxic effects on the heart as arrhythmias, acute myocardial infarction, and sudden death have been recorded. Moringa oleifera extract (MOE); is a herbal extract used to treat various diseases due to its antioxidant effect. **Aim;** This study was designed to evaluate the efficacy of MOE as a protective agent against cardiotoxicity induced by ND. **Material and methods;** Thirty-two adult male albino rats were allocated into four groups. Control group; MOE treated group; rats were given MOE by oral gavage (400 mg/kg/day) for four weeks. ND group; rats were injected ND S.C; at a dose of 20 mg/kg/week for four weeks. ND+MOE-treated group; rats simultaneously administrated ND; (20mg/kg/week S.C.) with MOE (400 mg/kg/day by oral gavage) for four weeks. Serum levels of cardiac enzymes were estimated. Also; MDA, GSH, SOD, IL-6, TNF- α , and IL-10 levels in cardiac tissue were estimated. Cardiac samples were processed to light, an immune-histochemical study using anti-P53 and anti-CX43 antibodies as well as electron microscopic examination. Morphometric; and statistical studies were done. **Results;** In the ND group, serum levels of cardiac biomarkers and cardiac tissue levels of MDA, TNF- α , and IL-6 were significantly increased with significant diminution in the activity of catalase, SOD, diminished GSH, and IL-10 in the cardiac tissues. Light; microscopic examination showed wide endomysium, inflammatory cell infiltration, and lacerated and wavy cardiac muscle fibres were observed. There was a marked deposition of collagen fibres at areas of interrupted muscle fibres. Positive; P53 immuno-expression in the nuclei and decreased expression of CX43 were observed. Ultra-structurally; interrupted myofibrils, dilated sarcoplasmic reticulum, and a disorganized intercalated disc was observed. In (ND+MOE) group; showed marked amelioration in the cardiac architecture and ultrastructure, down-regulation of P53, and CX43 immuno-expressions, and a significant reduction in serum level of cardiac biomarkers, and cardiac tissue levels of MDA, TNF- α and IL-6 with a significant increase in activity of catalase, SOD, diminished GSH and IL-10 in the cardiac tissues. **Conclusion;** MOE could alleviate the cardio-toxic effects induced by ND in rats through anti-inflammatory, anti-oxidant; and anti-apoptotic effects.

Keywords: Moringa, Nandrolone, Cardiotoxicity, oxidative toxicity.

1. INTRODUCTION

Anabolic androgenic steroids (AAS) simulate testosterone hormone structurally and functionally. AAS; has been extensively used for therapeutic purposes in treating chronic renal diseases, inoperable breast cancer, and osteoporosis in postmenopausal women (Patanè et al.,

2020). Nandrolone-decanoate; (17 β -hydroxy-19-nor-4- androstane-3-one) is an anabolic steroid. Nowadays; it is commonly used by athletes and bodybuilders to increase their physical performance and muscle mass (Mullen et al., 2020). Abuse; of anabolic steroids

results in many organ dysfunctions (Vorona and Nieschlag, 2018). High doses of ND; induce toxic effects on the cardiovascular system as arrhythmias, hypertension, altered lipid profiles, acute myocardial infarction, and sudden death have been recorded (Rosca et al., 2019; Melhem et al., 2020). The supra-physiological administration of AAS leads to endothelial dysfunction, alteration of cholesterol levels, oxidative stress, and inflammation. This increases morbidity and mortality due to its cardiac and metabolic consequences (Liu and Wu, 2019).

Numerous natural foodstuffs contain several phytochemical compounds expectant to guard the heart and blood vessels from further damage (Shaito et al., 2020). Geographically; Moringa-oleifera is dispersed from equatorial Africa to east India. It; is identified as the "miracle tree" because it has been used in nutrition and medicine.

All parts of this plant species, including leaves, roots, seeds, fruit, and flowers,

2. MATERIALS AND METHODS

2.1 Chemicals and drugs:

Nandrolone-Decanoate; is known commercially as Deca-Durabolin. It; was gained from (Chemical industrial Development Co. for the Nile Company for Pharmaceuticals and Chemical Industries, Egypt.). It; is available in the form of ampoules. Every vial; contains 50 mg/mL of the active ingredient in an oily solution.

Moringa-oleifera; was gained from the Egyptian Scientific Society for Moringa at the National Research Centre in Dokki, Giza, where it has been stored at the Horticulture and Crops, Technology Department with a voucher specimen number (Voucher No. MO19).

Preparation of Moringa-oleifera extract (Aqueous extraction):

The leaves were scattered as a thin layer under a shadow with no exposure to direct sunlight to be air dried, with continuous turning over of the leaves to avoid mould and keep their green colour. Until; they were crispy when touched. Then; leaves were grinded with a blender to powder

contain numerous natural antioxidant components, such as flavonoids, ascorbic acid, carotenoids, and phenolics (Mumtaz et al., 2021). Moringa-oleifera extract (MOE) is used to treat many disorders, such as anaemia, diabetes, and infectious and cardiovascular diseases.

The moringa-oleifera extracts (MOE); that are known that have functional activities associated with cardiovascular disorders are isoquercetin, α -Lrhamnopyranosyl lincosamide, quercetin, and isothiocyanate (Alia et al., 2022). Several studies; suggested that MOE act as a cardio-protective for structural integrity from damage and ameliorative for cardiac contractility through its antioxidant, anti-inflammatory, and anti-apoptotic properties (Aekthamarat et al., 2019; Khalil et al., 2020).

Altos of bodybuilders presented at the hospital with cardiac disorders, so this experimental study aimed to detect cardio-toxicity induced by ND and to evaluate the protective efficacy of MOE against this toxicity.

form. Twenty grams (20 g) of the Moringa-oleifera powder was dissolved in 100 ml of distilled water for 24 hours. Then; it was filtered using a white riddle cloth, and the deposit was dried to obtain the dry weight of the deposit, it was subtracted from the original weight to know the amount of Moringa-oleifera that dissolved in 100 ml of distilled water (Osonuga et al., 2020).

2.2 Animals:

Thirty-two adult male albino rats weighing 160 ± 20 g were purchased from an animal breeding facility used for experiments (Helwan-Cairo). They; were kept in animal housing at the Anatomy and Embryology department of the Benha Faculty of Medicine, eight per cage in a well-ventilated environment at room temperature. For seven days before the start of the trial, they provided free access to standard food (rat-feeding pellets bought from an animal breeding farm). Animals; were handled following the Benha Faculty of Medicine's protocol for

managing experimental animals throughout the study.

2.3 Design of the experiment:

Rats were divided into four groups at random, each of 8 rats; the animals in Group I (normal vehicle control), sesame oil S.C. injection. The Group II (ND), rats were injected with nandrolone-decanoate S.C.; at a dose of 20 mg/kg/week for four weeks diluted in sesame oil (Sretenovic et al., 2020). Group III (MOE), rats were treated with moringa oleifera (400 mg/kg/day by oral gavage) for four weeks (Aja et al., 2015). Group IV (ND+MOE); rats simultaneously administered nandrolone-decanoate (20mg/kg/week S.C.) with moringa oleifera (400 mg/kg/day by oral gavage) for four weeks.

2.4 Methods:

Animals from each group were given ether inhalation anaesthesia after the allotted time for each group. Blood samples were obtained immediately from IVC and placed in non-heparinized glass tubes for the biochemical study; the blood samples were centrifuged for 15 minutes at 3000 rpm; the serum was collected and kept at -20°C .

All rats' left ventricles were quickly sampled for cardiac tissue, and half of each group's samples were fixed in 10% neutral buffer formalin for light microscopy; for the electron microscopic study, the other half of the cardiac muscles were fixed in 1% glutaraldehyde in phosphate buffer (Kuo, 2007).

To investigate oxidative stress parameters, additional cardiac specimens were removed from the right ventricles of all rats and kept at 80°C .

2.5 Biochemical study

2.5.1 Measurement of cardiac biomarkers

According to a technique published by Whitaker, 1969, serum lactate dehydrogenase (LDH) activity was assessed using kits from Vitro Scientific in Cairo, Egypt; using kits from VitroScient, a kinetic method was used to measure the concentration of creatine kinase (CK) in serum According to a technique published by Zilva and Pannall, 1985; An assay kit

(BioAssay Systems, Hayward, CA, USA) was used to measure the activity of creatine kinase-muscle brain (CK-MB) in serum based on the technique published by Bishop et al., 1971; A kit was used to measure the serum's myoglobin concentration (Reactivos Spinreact, Girona, Spain) according to the technique published by Müller et al., 2000; Using a Cobas h 232 immunoassay analyzer (Rache Diagnostics, Mannheim, Germany) with a sensing range of 0.1-3 g/L, the cardiac troponin T level in whole blood was determined.

2.5.2 Measurement of the Biomarkers of Cardiac Oxidative Stress:

Catalase (CAT) activity measurements were used to identify the oxidative cascade, and superoxide dismutase activity (SOD), Using specialized diagnostic kits purchased from Laboratory Bio-diagnostic Co, malondialdehyde (MDA) and reduced-glutathione (GSH) levels were measured; According to the methods published by Aebi, 1984; Misra et al., 2014; Buege and Aust, 1978 and Ellman, 1959 respectively.

2.5.3 Measurement of inflammatory markers

Enzyme-linked immunosorbent assay (ELISA; TP-Reader, Thermoplate) was used to evaluate the levels of the cardiac inflammatory cytokines IL-6, TNF-, and IL-10 in ventricles samples (50 mg) following the manufacturer's instructions (Meador et al., 2008).

2.6 Histological study

2.6.1 Light microscopic study

The left ventricles samples were formed as paraffin slices (5um) and stained using the:

1. Hematoxylin & eosin (H&E) stain for routine histological examination (Bancroft and Layton, 2013).
2. Masson trichrome stain for collagen fibres detection (Keirnan JA, 2015).
3. Immunohistochemical staining via anti-P53 and anti- connexin 43
We are using primary anti-p53(Clone Do-7, Code-Nr. M7001; Dako, Carpentaria, California, USA) or anti-Cx43 (polyclonal

rabbit anti-rat, Santa Cruz, CA), respectively (Antunes et al. 2013).

Images of cardiac sections were taken with Olympus digital camera (E420, China) connected to the Olympus BX51 microscope, using an objective lens $\times 40$.

2.6.2 Electron microscopic study

Ultrastructure examination of cardiac samples fixed in 1% glutaraldehyde was done according to (Kuo J, 2007); the ultrathin slices were studied in the faculty of medicine, at Tanta University, Egypt, using a TEM JEOL JEM-100 SX.

2.7 Morphometric study:

1. percentage of collagenous fibres area in sections stained with Masson's trichrome.
2. The percentage of P53-positive nuclei in immunostained sections
3. Percentage area of positive Cx43 immuno-expression in immunostained sections

3. RESULTS

3.1 Effect of nandrolone-decanoate (ND) and moringa oleifera (MOE) on cardiac biomarkers:

Rats given ND; showed a significant increase in blood levels of LDH, CK, CK-MB, and myoglobin; when compared to rats in the control group. Rats treated with ND alone or in combination with MOE did not significantly differ from the control group in their serum level of troponin-T. Rats; treated with MOE with ND showed a significant decrease in serum levels of LDH, CK, CK-MB, and myoglobin compared to ND (Table 1).

3.2 Effect of ND and MOE on Oxidative stress biomarkers:

Rats given ND; displayed a significant increase in MDA levels in their cardiac samples compared to the rats in the control group; Rats given ND displayed a significant decrease in catalase and SOD activity, as well as a decrease of GSH in the heart tissues, compared to the control group; All oxidative stress markers changed differently in rats given MOE and ND, compared to the ND group (table 2).

3.3 Effect of ND and MOE on cardiac inflammatory markers:

Rats given ND; showed a significant increase in TNF- and IL-6 levels in their

The measurements were done in six microscopic fields that were not overlapping the ventricular wall for each rat by using the image analysis program "Leica Quin 500" software image analyzer.

2.8 Statistical analysis:

SPSS version 16 software (SpssInc, Chicago, ILL Company) was used to tabulate and analyze the collected data; Data were expressed as mean \pm standard deviation; By using the Shapiro-Wilks test, they assumed normality; $P > 0.05$, as proved to be non-parametric, the Kruskal Wallis test was used to detect the difference among the studied groups. Following significant Kruskal Wallis tests, post hoc multiple comparisons using the Bonferroni test were used to find significant pairs; In this work, 0.05 was designated as the acceptable level of significance. (it was considered significant if $P < 0.05$).

cardiac samples compared to the control group; Rats given ND showed a significant drop in IL-10 in the cardiac tissues, compared to the control group. A significant reduction in TNF- α and IL-6 levels with significant elevation in IL-10 level in rats treated with MOE with ND was noted, compared to ND (Table 3).

Light microscopic results:

Light microscopic analysis of cardiac tissues stained with H&E of control and MOE-treated group revealed a similar picture and exhibited the longitudinal cut myocardium's normal histological structure. The myocardium is formed of regularly arranged cardiac fibres with myofibrils parallel to the longitudinal axis of the muscle fibres; Myocytes had cross striations in acidophilic cytoplasm and central oval nuclei; There was thin connective tissue known as endomysium, separating the fibroblasts with flat nuclei and myocardial blood capillaries, from the cardiac myocytes.

In the ND-treated group, the heart muscle's displayed abnormal architecture, which includes a wide endomysium and dilated blood vessels, extravasated blood, and inflammatory cell infiltration. The cardiac muscle fibres were seen to be

located, hyalinized, and wavy. There were dark pyknotic nuclei in some cardiomyocytes and peripheral dark nuclei in others. Others displayed perinuclear cytoplasmic vacuoles. Numerous myocytes with profoundly eosinophilic cytoplasm were observed. In ND+MOE treated group; Normal cardiac muscle architecture was preserved to some extent. Regularly organized cardiac muscle fibers with central vesicular nuclei with wide separation of the muscle fibers are seen. Some cardiomyocytes have darkly stained nuclei (**fig 1**).

Light microscopy revealed the control and MOE groups in Masson's trichrome-stained sections were the same and showed tiny collagen fibers between the heart muscle fibres in the endomysium. The collagen fibers were notably deposited by the ND group in the sites of the interrupted fibres of the heart muscle. ND+MOE treated group revealed a little collagen fibres accumulation between heart muscle fibres (**fig.2**).

4.5 Immuno-histochemical results:

Immunohistochemical examination of the myocardial expression of P53 revealed that the control group and MOE-treated groups showed negative P53 immun-expression in the cardiomyocyte nuclei. The ND-treated group showed positive P53 immun-expression in the nuclei of the cardiomyocyte. The ND+MOE-treated group showed a weak positive P53 immune reaction in the nuclei of cardiomyocytes (**fig3**).

Immunohistochemical examination of myocardial immuno-expression of Cx43 revealed that control and MOE-treated groups: had regular immuno-expression of Cx43 in the intercalated discs. The group treated with ND displayed weak immuno-expression of Cx43 in the intercalated discs. The group treated with ND+MOE displayed intense immuno-expression of Cx43 in the intercalated discs (**fig4**).

4.6 Electron microscopic results:

The electron microscopic examinations of the myocardium of control and MOE-treated groups were similar to the normal histological structure. They revealed that regular transverse striations of myofibrils between two subsequent dark Z-lines were

structured as sarcomeres; the light I-band was on the sarcomere's periphery, and the dark A-band was in the center. A light H-zone could be seen in the center of the dark A-band. Regular rows of variable-sized abundant mitochondria were seen between the myofibrils. The oval nuclei had finely dispersed chromatin encircled by a regular intact nuclear membrane. Intact intercalated disc in between myocytes with a step-like pattern formed of adherens junction (AJ) and gap junction (**Fig5a,5b**) & (**6a,6b**).

The electron micrograph of cardiac myocytes from the ND group showed a loss of regular arrangement of myofibrils due to focal areas of myofibril damage and interrupted Z lines. An irregular outline of the nuclear membrane and condensed chromatin was observed. Between myofilaments, there are dilated sarcoplasmic reticulum and dense mitochondria with irregular shapes and arrangement. The intercalated disc was dilated, and there was vast intracellular space between myocytes. Excessive glycogen granules were observed (**Fig7a,7b**).

The electron micrograph of cardiac myocytes from the ND + moringa group revealed the restoration of myofibril transverse striations in a regular sequence and a typical sarcomere pattern between two successive Z-lines. A nucleus with a regular outline of the nuclear membrane and finely dispersed chromatin was observed. Between myofilaments, there were sarcoplasmic reticulum and variable-sized dense mitochondria arranged in rows in between myofibrils. Adherens junction part of the intercalated disc appeared well organized as a step-like pattern. Excessive glycogen granules were observed (**Fig7**).

4.7 Morphometric results:

All morphometric results are demonstrated in Table (4):

A significant increase in the percentage area of collagen content in heart tissue of sections of rats treated with ND compared with those in control and MOE groups ($p < 0.05$). A significant decrease in the percentage area of collagen content in sections of rats treated with ND+MOE-

treated group compared with those in the ND group ($p < 0.05$)

A significant increase in the percentage area of p53 expression in sections of rats treated with ND compared with those in control and MOE-treated groups ($p < 0.05$). A significant decrease in the percentage area of p53 expression in sections of rats treated with the ND+MOE group compared with those in ND-treated group ($p < 0.05$).

A significant decrease in the percentage area of CX43 expression in sections of rats treated with ND compared with those in control and MOE-treated groups ($p < 0.05$). A significant increase in the percentage area of CX43 expression in sections of rats treated with ND+MOE-treated group compared with those in ND-treated group ($p < 0.05$).

Table (1): Changes in serum (LDH), (CK), (CK-MB), Myoglobin, and Troponin-T levels in different groups. The value represents mean \pm SD, a, Significant difference from the control group at $p < 0.05$. b, Significant difference from the MOE-treated group at $p < 0.05$, and c, Significant difference from the ND-treated group at $p < 0.05$

Group	LDH (U/L)	CK (U/L)	CK-MB (ng/ml)	Myoglobin (ng/ml)	Troponin-T (pg/ml)
	Mean \pm SD	Mean \pm SD	Mean \pm SD	Mean \pm SD	Mean \pm SD
Control	112.58 \pm 6.7	769.50 \pm 8.5	0.202 \pm 0.03	13.8 \pm 1.34	0.016 \pm 0.005
MOE	107.75 \pm 7.8	748.80 \pm 12.3	0.211 \pm 0.10	13.2 \pm 0.63	0.016 \pm 0.003
ND	139.10 \pm 6.0 ^{a,b}	955.00 \pm 13.9 ^{a,b}	0.370 \pm 0.04 ^{a,b}	16.6 \pm 0.30 ^{a,b}	0.019 \pm 0.010
ND+MOE	123.61 \pm 8.9 ^{a,b,c}	817.30 \pm 15.4 ^{a,b,c}	0.260 \pm 0.08 ^c	15.08 \pm 0.95 ^{a,b,c}	0.018 \pm 0.002

Table (2): Malondialdehyde content (MDA), reduced glutathione content (GSH), catalase activity (CAT), and superoxide dismutase activity (SOD) in the heart of rats treated with NA and MOE separately and in combination. The value represents mean \pm SD, a, Significant difference from the control group at $p < 0.05$. b, Significant difference from the MOE-treated group at $p < 0.05$ and c, Significant difference from the ND-treated group at $p < 0.05$

Group	MDA (nmol/g tissue)	GSH (mg/g tissue)	SOD (u/mg protein)	CAT (mmol/min/g tissue)
	Mean \pm SD	Mean \pm SD	Mean \pm SD	Mean \pm SD
Control	50.4 \pm 1.6	157.0 \pm 2.00	57.0 \pm 2.0	0.49 \pm 0.017
MOE	42.4 \pm 2.6	154.8 \pm 4.37	55.4 \pm 2.6	0.48 \pm 0.018
ND	108.0 \pm 4.9 ^{a,b}	116.1 \pm 3.18 ^{a,b}	45.0 \pm 1.7 ^{a,b}	0.24 \pm 0.017 ^{a,b}
ND+MOE	62.9 \pm 17.9 ^{a,b,c}	147.3 \pm 8.03 ^{a,c}	51.9 \pm 3.4 ^{a,c}	0.40 \pm 0.068 ^{a,b,c}

Table (3): Changes in serum TNF- α , IL6, and IL-10 levels in the heart of rats treated with NA and MOE separately and in combination. The value represents mean \pm SD, a, Significant difference from the control group at $p < 0.05$, b, Significant difference from MOE-treated group at $p < 0.05$, and c, Significant difference from ND-treated group at $p < 0.05$

Group	TNF- α (Pg/mg protein)	IL-6 (Pg/mg protein)	IL-10 (Pg/mg protein)
	Mean \pm SD	Mean \pm SD	Mean \pm SD
Control	225.0 \pm 9.2	150 \pm 6.0	220 \pm 8.1
MOE	228.5 \pm 2.4	151 \pm 3.9	220 \pm 7.1
ND	268.8 \pm 14.0 ^{a,b}	220 \pm 8.8 ^{a,b}	190 \pm 7.7 ^{a,b}
ND+MOE	225.4 \pm 10.1 ^c	165 \pm 8.0 ^{a,b,c}	210 \pm 7.1 ^c

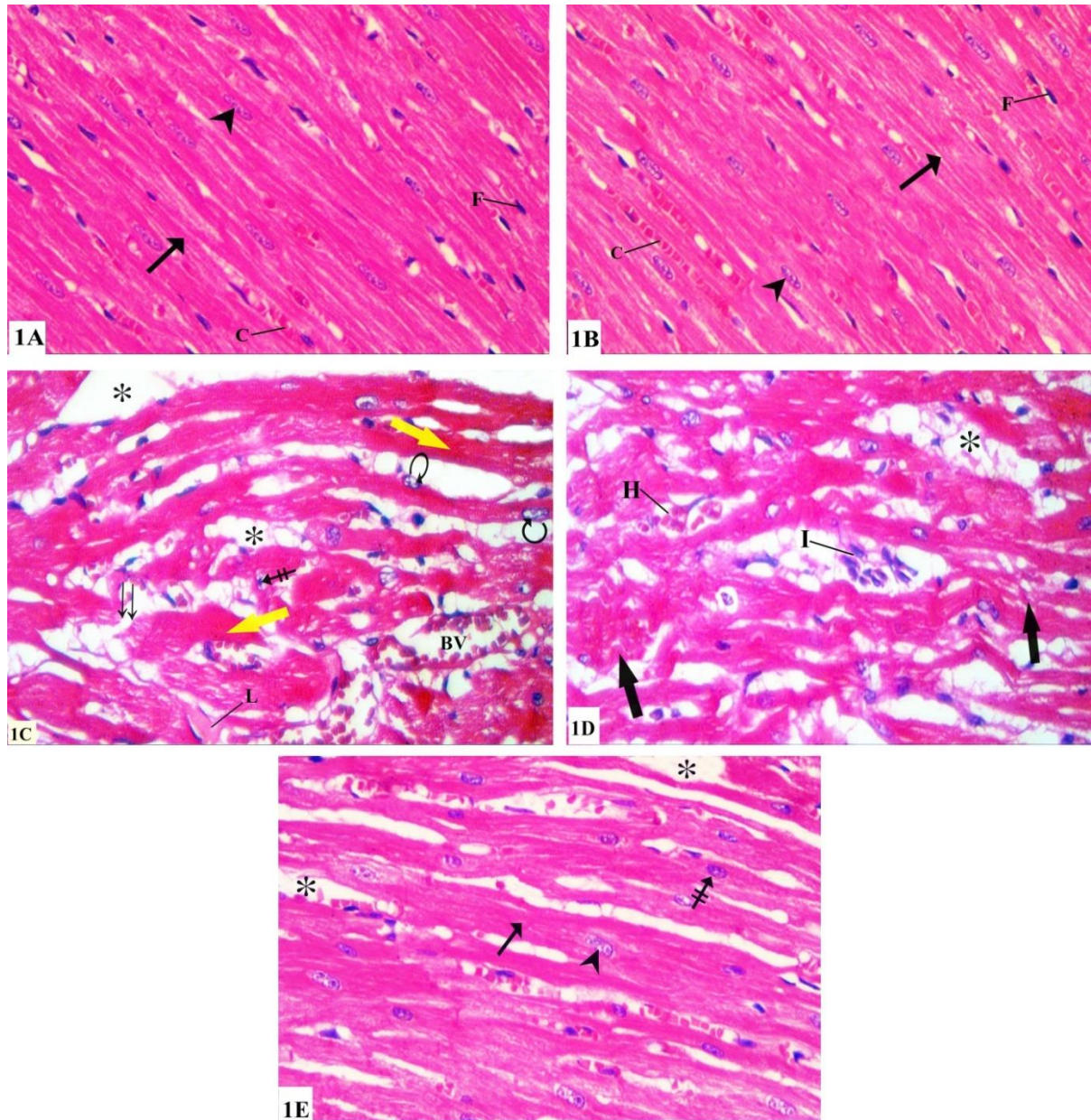


Fig.1 Photomicrographs of longitudinal sections of rat myocardium:(1A) for the control group; and (1B) for MOE-treated group showing; myocardium formed of regularly arranged cardiac fibers with myofibrils parallel to the longitudinal axis of the muscle fibres (arrow). Myocytes show cross striations in acidophilic cytoplasm and central oval nuclei (arrowhead). There is delicate connective tissue separating the cardiac myocytes containing blood capillaries (c) and fibroblasts with flat nuclei (F). (1C) furthermore (1D) are for the ND-treated group showing; disturbance of cardiac muscle architecture with wide spaces (asterisks) between cardiac muscle fibers, lacerated(double arrows), wavy (thick black arrow), and hyalinized (L) cardiac muscle fibres, dilated blood vessel (B.V) and extravasated blood (H) and inflammatory cellular infiltration (I) are observed. Some cardiomyocytes have dark pyknotic nuclei (crossed arrows), and others have dark peripheral nuclei (curved arrows). Others show perinuclear vacuolation(v). Numerous myocytes with deeply eosinophilic cytoplasm (yellow arrow). (1D) for the ND+MOE-treated group showing; the normal architecture of cardiac muscle was partially preserved. The regular arrangement of cardiac muscle fibres (arrow) with central vesicular nuclei (head arrow) is observed with wide separation (asterisks) of the muscle fibres. Some cardiomyocytes have darkly stained nuclei (crossed arrow). (H&E X400).

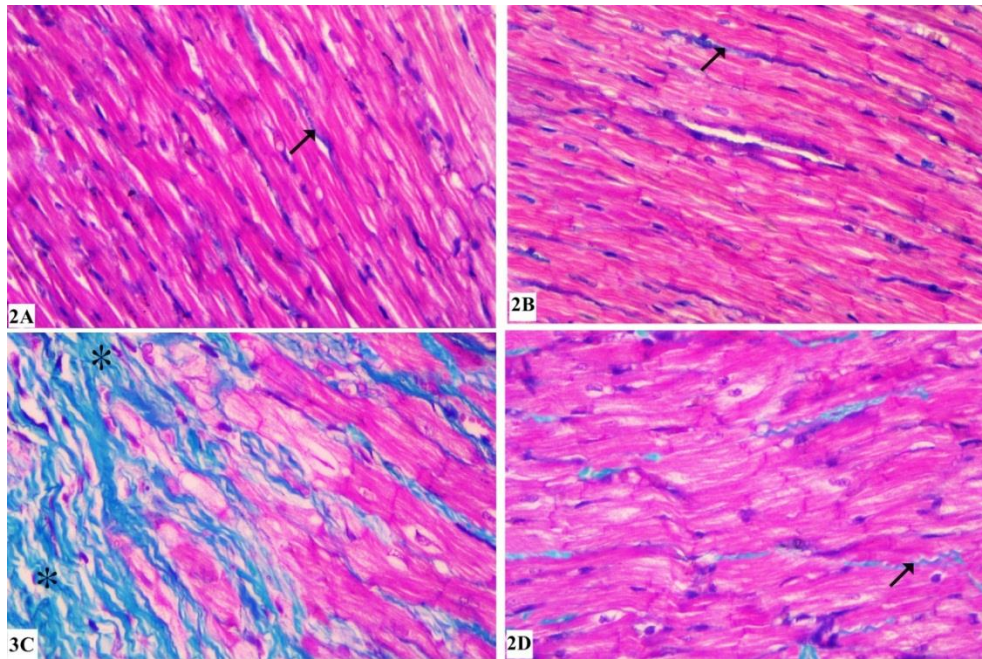


Fig. 2 Photomicrographs of longitudinal sections of rat myocardium: (A) ;for Control; and (B); for MOE-treated groups; showing fine collagen fibres (arrows) in the endomysium in between fibres. (C); for ND-treated group showed; apparent deposition of collagenous fibres (asterisks) at areas of interrupted fibers of cardiac muscle. (D); for ND+MOE-treated group showed; mild deposition of collagen fibres in between fibres of cardiac muscle (arrows)

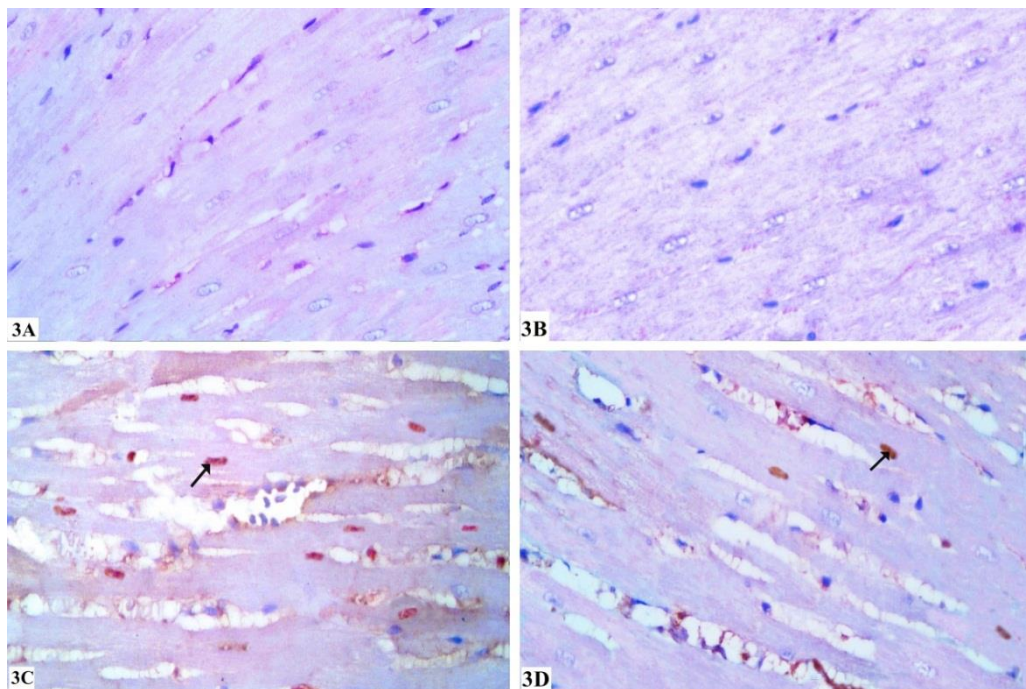


Fig.3. Photomicrographs of longitudinal sections of rat myocardium for Immunohistochemical expression of P53 (400×) showing: (A); for control group and (B); for MOE treated group: showing negative P53 immune reaction in the nuclei of cardiomyocyte. (C); ND-treated group: showing positive P53 immune reaction in the nuclei (arrows) of the cardiomyocyte. (D); for ND+MOE-treated group: showing weak positive P53 immune reaction in the nuclei (arrows) of the cardiomyocyte.

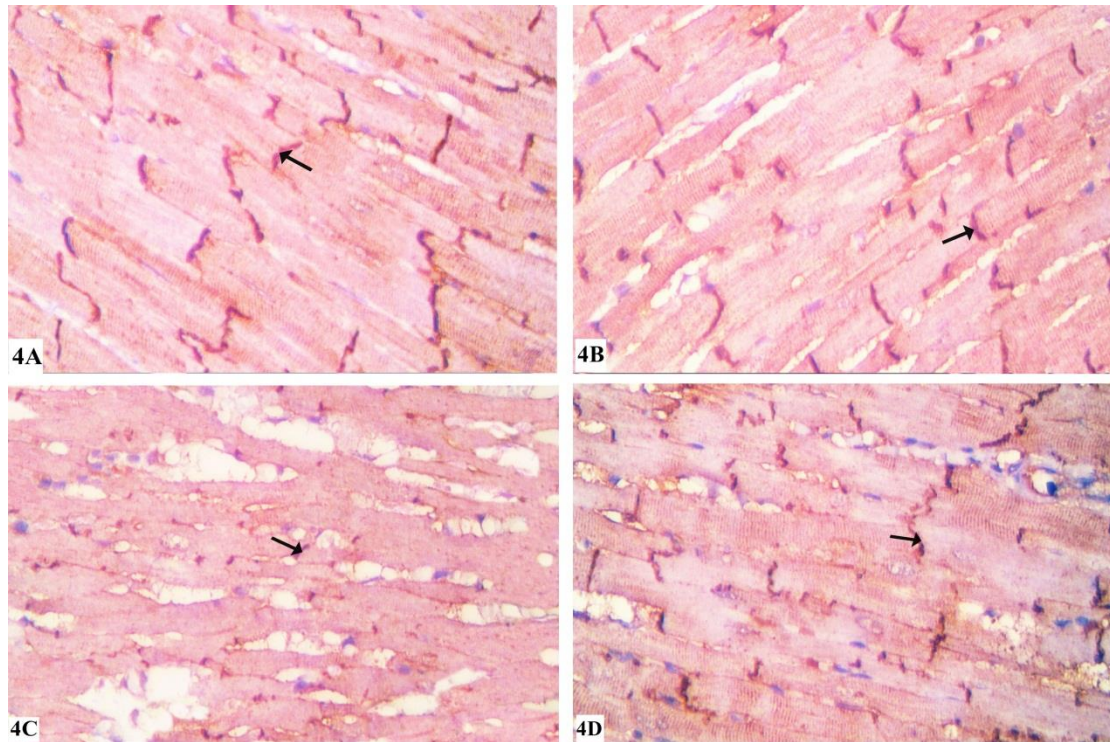


Fig.4 Photomicrographs of longitudinal sections of rat myocardium for Immunohistochemical expression of Cx43 (400 \times). (A); for Control and (B); for MOE groups showing: regular expression of Cx43 in the intercalated discs (arrow). (C); for The ND-treated group showed; weak expression of Cx43 in the intercalated discs (arrow). (D); for ND +MOE treated group showed; strong expression of Cx43 in the intercalated discs (arrow).

Table (4): The percentage area of collagen content, p53 immuno-expression, and CX43 immuno-expression in cardiac rat tissue of rats treated with NA and MOE separately and in combination. Results are expressed as Mean \pm SD (n = 8), a, Significant difference from the control group at $p < 0.05$, b, Significant difference from MOE-treated group at $p < 0.05$, and c, Significant difference from ND-treated group at $p < 0.05$.

Group	P53 (%of protein expression)	Masson (%of collagen content)	Connexin (%of protein expression)
Control	1.003 \pm 0.64	0.84 \pm 0.15	6.14 \pm 0.08
MOE	0.913 \pm 0.37	0.85 \pm 0.19	6.17 \pm 0.06
ND	8.628 \pm 1.18 ^{a, b}	2.07 \pm 0.24 ^{a,b}	3.41 \pm 0.04 ^{a,b}
MOE+ND	5.31 \pm 1.40 ^{a,b,c}	1.53 \pm 0.23 ^{a,b,c}	4.54 \pm 0.13 ^{a,b,c}




Fig.5,6 An electron micrograph of cardiac myocyte for(5a,5b) for control and (6a,6b) for MOE-treated groups showing: regular transverse striations of myofibrils formed of dark (A) and light (I) bands bisected by (Z) lines, the distance between 2 Z-line is called sarcomere (S). The center of each (A) band has a pale (H) zone, variable-sized mitochondria (m) arranged in rows in between myofibrils. Oval nucleus (n) with finely dispersed chromatin and regular nuclear membrane. Standard appearance of the intercalated disc formed of adherens junction (AJ) and gap junction (GA).

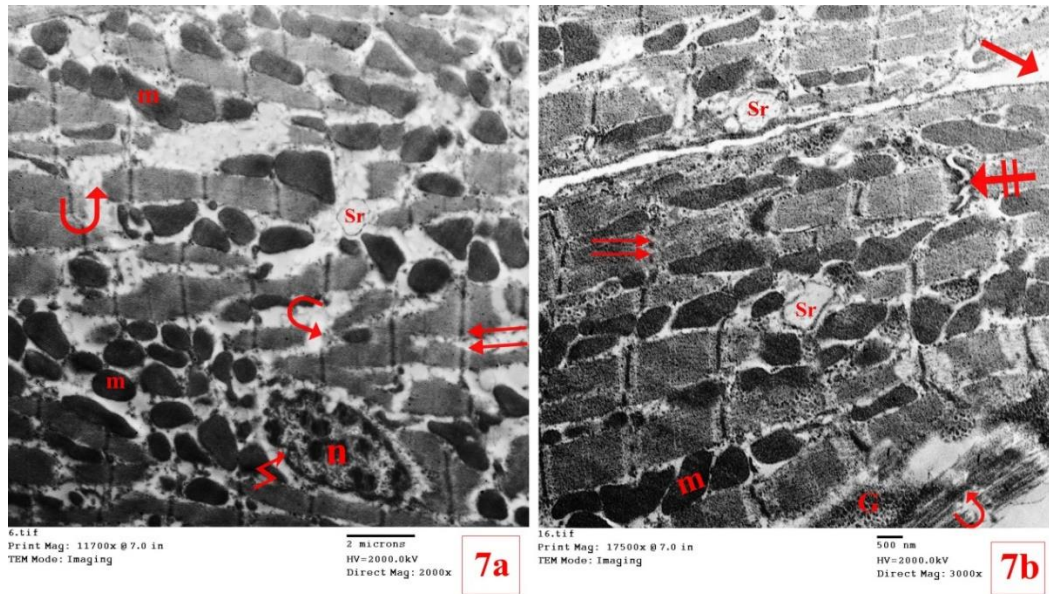


Fig.7 An electron micrograph of two cardiac myocytes from the ND-treated group showing: the loss of regular arrangement of myofibrils due to focal areas of myofibrillar damage (curved arrow) interrupted Z lines (double arrow). A nucleus (n) with an irregular outline of the nuclear membrane (zigzag line) and condensed chromatin is observed. Between myofilaments, there are dilated sarcoplasmic reticulum (Sr) and dense mitochondria (m) with irregular shapes and arrangements. The intercalated disc is dilated (crossed arrow). Vast intracellular space (arrows) between myocytes is observed. Excessive glycogen granules (G) are observed.

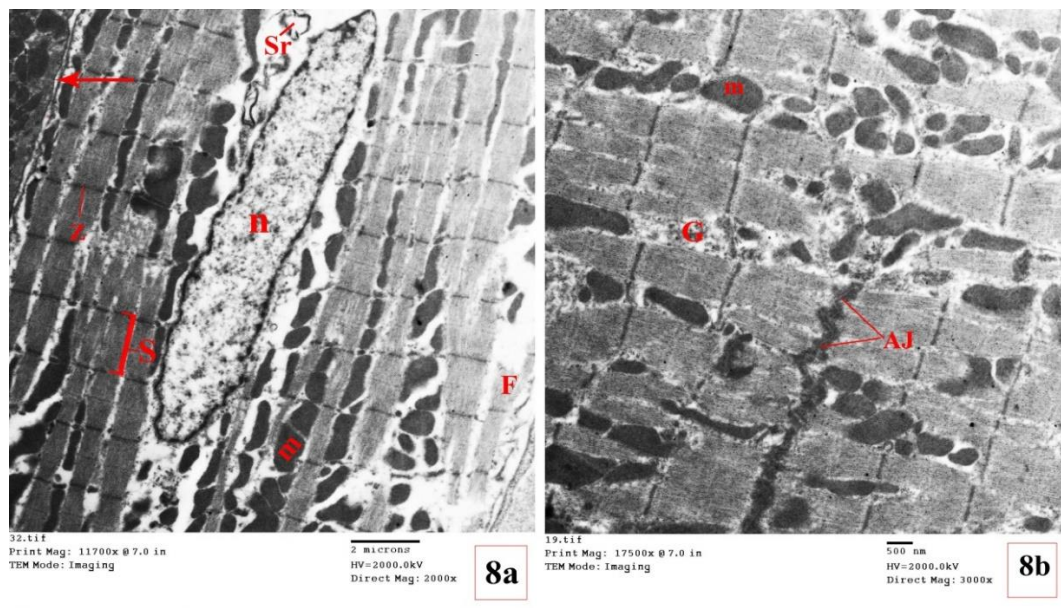


Fig.8 An electron micrograph of two cardiac myocytes from the ND+MOE-treated group showing: the return of regular arrangement of myofibrils regular transverse striations of myofibrils with a standard pattern of sarcomeres (S) between 2 (Z) lines. A nucleus (n) with a regular outline of nuclear membrane and euchromatin is observed. Between myofilaments, there are sarcoplasmic reticulum (Sr) and variable-sized dense mitochondria (m) arranged in rows in between myofibrils. The Adherence junction (AJ) part of the intercalated disc appears. Standard form of excessive glycogen granules are (G) observed.

4. DISCUSSION

Evidence support that non-therapeutic doses of ND could easily interrupt the homeostasis of the heart of Wistar rats (**Almaiman et al., 2019**). Several studies have confirmed the cardioprotective potency of MOE in cardiac disorders (**Alia et al.,2022**). The current work aimed to evaluate the efficacy of MOE in preventing cardiotoxicity induced by ND.

In this investigation, ND significantly raised serum levels of LDH, CK, CK-MB, and myoglobin compared to the control group, but it did not significantly alter troponin-T levels. These results matched with research that stated that administration of boldenone in rats causing a significant rise in blood levels of myoglobin, CK, CK-MB, and LDH in treated rats compared to control (**El gharabawy et al., 2020**). Also; **Ali et al. (2018)** recorded a significant rise in serum cardiac marker CK-MB in the group treated with ND only. CK-MB is considered an indicator of myocardial necrosis (**Ulla et al., 2017**). Alterations in the levels of cardiac enzymes and cardiac markers have been defined in myocardial infarction(**Miltonprabu & Thangapandiyan, 2015**).

In this study, our results revealed a significant rise in MDA level and significant decreases in reduced GSH level, the activity of catalase, and the activity of SOD in cardiac muscles after ND injection. The capability of ND to elevate the level of oxidative stress biomarkers and disturb anti-oxidant defense was previously demonstrated by [**Salem and Alnahdi, 2020; Mohammed et al., 2020**] who studied the effect of ND on the kidney and testis, respectively.

When the activities of anti-oxidant enzymes were reduced, the capacity of scavenging ROS in the cells was decreased. Subsequently, ROS accumulates in the cells, attacking the biomolecules (DNA, proteins, and lipids). This disrupts cell function and triggers the onset of numerous illnesses (**Kumar et al.,2021**). Previous studies detected a decrease in anti-oxidant enzyme activity

as well as increasing thiobarbituric acid-reactive substances representing impaired redox homeostasis (**Lima et al., 2020**).

In this study, compared to the control group, rats given ND had significantly higher levels of TNF- α and IL-6 also had significantly lower levels of IL-10 in their cardiac tissues. This was in agreement with **Magalhães et al. (2020)**, who found that ND induced high inflammatory signals by increasing IL-1 β , TNF- α , and IL-6 local levels in the retroperitoneal fat pad in the treated group compared to the control group.

Several pro-inflammatory mediators are generated by some inflammatory cells ,such as neutrophils and macrophages, which infiltrate the site of injury, including TNF- α and IL-6. These cytokines are crucial for the activation of myofibroblasts and the stimulation of resident fibroblast proliferation (**Thomas & Grisanti, 2020**).

Our light microscopic results in ND treated group proved previous findings and revealed widened endomysium between myofibers. There were focal areas of wavy and lacerated myofibers. Vacuolated eosinophilic homogenous cytoplasm, pyknotic and karyolytic nuclei were noticed. These histopathological changes are in agreement with previous investigators confirming the success of the current model [**Elgendy et al.,2018; Soliman et al.,2017; Abdelhafez et al.,2014**]. **Kahal & Allem (2018)** noticed elongation, severe laceration, and damage of the cardiac myofibers with vascular congestion, which remain after stopping ND treatment. He suggested that this could be the cause of some cardiac diseases in AAS consumers.

In the current study, we noticed peripherally located nuclei in myocytes in ND treated group. It has been described that nandrolone activates protease enzymes that break down desmin filaments that form a cytoskeleton network extending from the sarcolemma to the nuclear surface, thus causing nuclear

dislocation of cardiac myocytes to the periphery (Cao et al.,2021).

The present work showed blood vessel dilatation and extravasation of blood cells in between myofilaments. Previous research stated that AAS administration stimulated oxidative stress in rats, which could lead to dilatation and congestion of blood vessels. The production of vasodilator substances is stimulated by AAS, and this increases the permeability of the endothelium lining of blood vessels, allowing blood components to pass into the extravascular tissue (Sadowska-Krepa et al., 2011). Testosterone persuades apoptosis in cells of the smooth muscle of blood vessels through androgen receptor activation and ROS production; this causes dilatation of blood vessels (Lopes et al., 2014).

Another finding in the current study, as compared with a control group, the collagen fibres increased in sections of the group treated with ND. This was the same finding of Sretenovic et al. (2022), who found that NA alone or combined with swimming caused increase collagen content in heart tissue. The wide endomysium found in this study may be increased in the connective tissue components, particularly collagen fibres, and the degree of muscle damage.

A previous study stated a significant rise in the levels of MMP-2 and MMP-9 gene expression in the heart tissue and a significant increase in the TGF b1 level in the serum after ND administration (Ali et al., 2018). The injured cardiomyocytes produce high levels of profibrotic protein; TGF b1, which is attached to its receptor on the cell surface; this elevates the expression of fibrosis proteins; MMP-2 and MMP-9 gene, which stimulates cardiac fibrosis (Chang et al., 2014; Lai et al., 2015).

A transcription factor called p53 (tumor suppressor protein) controls the rate at which numerous genes involved in DNA repair and apoptosis are transcribed. (Tousson et al., 2011). The immunohistochemical results of this work displayed a significant rise in the expressions of apoptotic protein p53 in the ND group when compared with the control

group. The MOE treatments were able to prevent this increase in p53 expression. Our findings are consistent with those of El gharabawy et al. (2020), who discovered that the injection of boldenone into rats caused an increase in p53 expression in cardiac tissues. Also, these results agree with Saddick (2021), who noticed that; ND induced apoptosis in rat testes.

Ali et al. (2018) recorded a significant rise in the calcium level of cardiac mitochondria in ND-treated rats. It has been revealed that increase concentrations of intracellular calcium trigger the opening of the mitochondrial transition pores resulting in impairment of the permeability of the mitochondrial membrane that lead to the discharge of apoptotic factors such as cytochrome C ,also oxidative reaction induces DNA damage which activates P53, later on, apoptosis occurs (Liu & Wu, 2019).

In this study, there was a significant decrease in the expression of connexin 43 in sections of ND-treated rats compared to the control group. Atypical Cx43 expression is often accompanied by cardiomyopathy and arrhythmias (Elhadidy et al.,2020)

Ultrastructure study of the ND group showed disorganization of myofibrils, dilated sarcoplasmic reticulum, dense irregular shapes mitochondria and a disorganized intercalated disc was observed. These observed degenerative changes were supported by the previous study done in 2022 by Mohamed and Mohamed (2022), who reported the same findings in skeletal muscle after ND administrations.

In the current study, focal areas of myofibrils damage interrupted Z lines were noticed in the group treated with ND. This is in agreement with Elgendy et al. (2018), who explained that myofibril dismantles after ND treatment due to activation of Proteinase by increased calcium level in necrotic muscle. Thus Myofibril dismantling happened as a result of the myofibrils' Z lines, M lines, tropomyosin, troponins, and C proteins being digested out of them. Also, the dismantling of myofibril may occur due to

dysfunction of mitochondria that can result in decreased ATP synthesis and insufficient energy output, both of which are necessary for maintaining cell homeostasis and cellular protein synthesis. (Baines, 2010). Tofighi et al. (2017) attributed the cause of cardiomyocyte apoptosis after prolonged administration of AAS to oxidative stress, and accumulation of ROS leads to decrease cardiac proteins survival and stimulates pro-apoptosis proteins leading to cardiomyocyte apoptosis.

In the present study, Sarcoplasmic reticulum (SR) dilation was seen in the cardiomyocytes of the ND group. The pathological SR lead to calcium leak and, excessive mitochondrial calcium uptake causes mitochondrial calcium overload and ROS release that worsen mitochondrial dysfunction (Ruiz-Meana et al., 2019)

There was an apparent increase in glycogen granules in the ND group in our study. On the contrary, Hassan & Kamal (2013) revealed that, compared to the control group, ND treatment alone did not raise the glycogen content in heart tissue. ASS changes the tissue response to insulin-like growth factors (Soliman et al., 2017). We suggest that after ND-induced cardiotoxicity, mitochondrial dysfunction and ATP depletion occurred, this was compensated by an increase in glycogen content in cardiac muscle for anaerobic glycolysis to provide energy.

Remarkably, Compared to the ND group, rats treated with MOE and NA showed a significant decrease in serum levels of LDH, CK, CK-MB, and myoglobin, according to the study's findings. These results were indicating that MOE has a protective role on cardiotoxicity by reducing myocardial destruction and thus limiting the leakage of these enzymes from the myocardium. Like results were reported by Khalil et al. (2020), who studied the cardioprotective effect of MOE against tilmicosin cardiotoxicity. Also, Abd El-Motelp (2022) demonstrated that MOE could decrease the serum levels of CRP, CK, LDH, and ALT, troponin-1 which were elevated after doxorubicin cardiotoxicity.

Additionally, the current research has shown that treatment of MOE with ND led to a significant decrease in the MDA levels with an increase in the activities of CAT and SOD in addition to a decrease in GSH in the cardiac tissues. This was the same noticed by Mabrouki et al. (2020), who investigated the heart's anti-oxidant response to MOE in high-fat diet-induced obesity. Moreover, treatment of MOE with NA in this study significantly down-regulated the TNF- α and IL-6 levels and it up-regulated the IL-10 level in serum, when compared to the ND group, this was indicating that MOE exerts cardioprotective influence against ND toxicity. According to Aniss et al. (2020), MOE had ameliorated doxorubicin-induced cardiotoxicity through its anti-inflammatory effect by decreasing inflammation markers TNF- α and NF- κ B in a rat model.

The observed decrease in oxidative stress markers and down-regulation of pro-inflammatory following MOE administration may have been attributed to its phytochemical components including isothiocyanates carotenoids, α -tocopherol (Vit E) and flavonoids like quercetin, which have been demonstrated to have anti-inflammatory properties, (Gopalakrishnan et al., 2016; Sreeja et al., 2021). Additionally, it includes gallic acid, which has anti-oxidant and anti-inflammatory properties that have been shown to reduce the release of inflammatory mediators like TNF- α (El-Shehawi et al., 2021). Likewise, the ability of MOE to struggle with oxidative stress by scavenging free radicals through its contents such as Chlorogenic acid, phenolic acids, rutin, and quercetin (Sreeja et al., 2021). Quercetin is the essential content of MOE. It contains phenolic hydroxyl groups, which can reverse altered energy metabolism in the heart because they have anti-oxidant action and suppress ROS significantly (Zakaria et al., 2018).

These results were reinforced by improved cardiac histology in light and electron microscopic investigations. The cardioprotective properties of ingredients isolated from MO leaves prevent the

disruption of cardiac myofibrils and improve cardiac contractile function (Panda et al., 2013).

CONCLUSIONS

Through its anti-inflammatory, anti-oxidant, and anti-apoptotic actions, *Moringa oleifera* extracts (MOE) can potentially mitigate the cardiotoxic effects generated by nandrolone-decanoate (ND) in rats.

Ethical approval

All aspects of this research were done according to the principles and guidelines of the Ethics Committee of the Faculty of Medicine, Benha University, Benha, Egypt.

The study conformed to the "Guide for the care and use of Laboratory Animals" for the use and welfare of experimental animals, published by the US National Institutes of Health (NIH publication No. 85-23).

RECOMMENDATION

Prevent athletes and bodybuilders from abuse of nandrolone-decanoate.

CONFLICTS OF INTEREST AND SOURCE OF FUNDING

No source(s) of support in the form of grants, equipment, drugs, or all of these. No conflicts of Interest of each author

REFERENCES

- Abd El-Motelp, B. A. (2022):** Synergistic Therapeutic Effect of L-Carnitine Nanoparticles and *Moringa Oleifera* Against Doxorubicin Induced Cardiac Toxicity in Male Rats: Biochemical and Histological Study. *Biointerface Research in Applied Chemistry*, 13(2):1-1
- Abdelhafez, H.M. (2014):** Histological, histochemical and ultrastructural studies on the effect of Deca-Durabolin and whey protein isolate on cardiac muscle in adult male albino rats. *International Journal of Advanced Research*, 2(10), 164-187
- Aebi, H. (1984):** "Catalase," in *Methods of Enzymatic Analysis*, H. U. Bergmeyer, Ed., pp. 673-684, Academic Press, New York, NY, USA, 1984.
- Aekthamarat, D.; Pannangpetch, P. and Tangsucharit, P. (2019):** *Moringa Oleifera* Leaf Extract Lowers High Blood Pressure by Alleviating Vascular Dysfunction and Decreasing Oxidative Stress in L-NAME Hypertensive Rats. *Phytomedicine* 54, 9-16.
- Aja, P.M.; Ibiam, U.A.; Nwali, B.U.; Orji, O.U.; Edwin, N.; Afiukwa, C.A. (2015):** Evaluation of effects of ethanol extracts of *Moringa oleifera* and *Cajanus cajan* leaves on lipid profiles, in alloxan-induced diabetic albino rats. *Global Journal of Biochemistry and Biotechnology* 2015, 10, 71-76.
- Ali, D.M.; Labib, D.A.A. and Mohamed M.M.N. (2018):** The Protective Role Of Coenzyme Q10 Against Nandrolone Decanoate-Induced Cardiotoxicity In Rats: Biochemical, Genetic, Histological And Immunohistochemical Study. *Egypt J. Forensic Sci. Appli. Toxicol* Vol 18 (1), 19-34.
- Alia, F.; Putri, M.; Anggraeni, N. and Syamsunarno, M.R.A.A. (2022):** The Potency of *Moringa oleifera* Lam. as Protective Agent in Cardiac Damage and Vascular Dysfunction. *Front. Pharmacol.* 12:724439. doi: 10.3389/fphar.2021.724439
- Almaiman, A.A.; Almaiman, S.H.; Elagamy, E.I.; Al Wutayd, O.; Almarzuqi, M.; Alzunaidi, R. et al. (2019):** Side effects of anabolic steroids used by athletes at unaizah gyms, Saudi Arabia: A pilot study. *J Sports Med Phys Fitness*, Mar;59 (3):489-495.
- Aniss, N.N.; Rahman, Y.H.A. & Zaazaa, A.M. (2020):** Cardioprotective Effect of *Moringa Oleifera* against Doxorubicin Cardiotoxicity in Leukemia Rat Model. *Int. J. Pharm.*

- Phytopharmacological Res., 10 (2): 148–161.
- Antunes, E.; Borrecho, G.; Oliveira, P.; Brito, J.; Aguas, A. and Martins dos Santos, J. (2013):** Immunohistochemical evaluation of cardiac connexin43 in rats exposed to low-frequency noise. *Int J Clin Exp Pathol*, 6:1874–9.
- Baines, C.P. (2010):** The cardiac mitochondrion: nexus of stress.
- Bancroft, J.D. & Layton, C. (2013):** The hematoxylin and eosin. In: Suvarna, S.K., Layton, C., Bancroft, J.D. (Eds.), *Bancroft's Theory and Practice of Histological Techniques*, 7th ed. Churchill Livingstone /Elsevier, Philadelphia, USA, pp. 173–186.
- Bishop, C.; Chu, T. M. & Shihabe, Z. K. (1971):** "Single stable reagent for creatine kinase assay," *Clinical Chemistry*, vol. 17, p. 548, 1971.
- Buege, J.A. & Aust, S.D. (1978):** "[30] Microsomal lipid peroxidation," *Methods in Enzymology*, vol. 52, pp. 302–310, 1978.
- Cao, J.; Gao, Q.; Chen, H.; Wang, C.; Zhang, Q.; Wang, Z. & Li, Y. (2021):** Desmin correlated with Cx43 may facilitate intercellular electrical coupling during chronic heart failure. *Evidence-Based Complementary and Alternative Medicine*.
- Chang, H.C.; Chiu, Y.W.; Lin, Y.M.; Chen, R.J.; Lin, J.A.; Tsai, F.J. et al. (2014):** Herbal supplement attenuation of cardiac fibrosis in rats with CCl₄-induced liver cirrhosis. *Chinese Journal of Physiology*, 57:41-47.
- El gharabawy, R.M.; Aldubayan, M.A.; Alshaifani, M.A. & Ahmed A.S. (2020):** Beneficial Role of Rosemary Aqueous Extracts Against Boldenone Induced Cardiac Toxicity, Injury and Oxidative Stress, in Male Rats. *INTERNATIONAL JOURNAL OF PHARMACOLOGY*, 16(2), 136-144
- Elgendy, H.; Alhawary, A.; El-Shahat, M. and Ali, A. (2018):** Effect of anabolic steroids on the cardiac and skeletal muscles of adult male rats. *International Journal of Clinical and Developmental Anatomy*, 4 (1), 1-14.
- Elhadidy, M.G.; Elmasry, A.; Rabei, M.R. and Eladel, A.E. (2020):** Effect of ghrelin on VEGF-B and connexin-43 in a rat model of doxorubicin-induced cardiomyopathy. *Journal of Basic and Clinical Physiology and Pharmacology*, 31(1).
- Ellman, G.L. (1959):** "Tissue sulfhydryl groups," *Archives of Biochemistry and Biophysics*, 82 (1): 70–77.
- El-Shehawi, A.M.; Alkafafy, M.; El-Shazly, S.; Sayed, S.; Farouk, S.; Alotaibi, S. et al. (2021):** Moringa oleifera leaves ethanolic extract ameliorates high fat diet-induced obesity in rats. *Journal of King Saud University – Science* 2021, 33(6): 101552.
- Gopalakrishnan, L.; Doriya, K. & Kumar, D.S. (2016):** Moringa oleifera: A review on nutritive importance and its medicinal application. *Food science and human wellness*, 5(2), 49-56.
- Hassan, A. F., & Kamal, M. M. (2013):** Effect of exercise training and anabolic androgenic steroids on hemodynamics, glycogen content, angiogenesis and apoptosis of cardiac muscle in adult male rats. *International journal of health sciences*, 7(1), 47-60.
- Kahal, A. & Allem, R. (2018).** Reversible effects of anabolic steroid abuse on cyto-architectures of the heart, kidneys, and testis in adult male mice. *Biomedicine & Pharmacotherapy*, 106, 917-922.
- Keirnan, J.A (2015):** *Histological and histochemical methods, theory and practice*. 5th ed. Scion Publishing limited Press; 2015. UK ISBN 978 1 907904 32 5 Pages: 571.
- Khalil, S.R.; Abdel-Motal, S.M.; Abd-Elsalam, M.; Abd El-Hameed, N.E. & Ashraf, A. (2020).** Restoring strategy of ethanolic extract of Moringa oleifera leaves against Tilmicosin-induced cardiac injury in rats: Targeting cell apoptosis-

- mediated pathways. *Gene*, 730, 144222. 10.1016/j.gene.
- Kumar, V.; Abbas, A.K.; Fausto, N. and Aster, J.C. (2021):** Robbins and Cotran pathologic basis of disease. 10th ed. Philadelphia: Elsevier health sciences (p) Ltd; P.52-54.
- Kuo, J. (2007):** Electron Microscopy, Methods and Protocols 2nd edition. Humana Press Inc, Vol. 54 No. 4/2007, 887-888.
- Lai, C.H.; Han, C.K.; Shibu, M.A.; Pai, P.Y.; Ho, T.J.; Day, C.H.; et al. (2015):** Lumbrokinase from earthworm extract ameliorates second-hand smoke-induced cardiac fibrosis. *Environmental Toxicology*, 30:1216-1225.
- Lima, E.M.; Cassaro, K.O.D.S.; Silva, C.L.D.; Silva, M.A.; Poltronieri, M.P.; Nascimento, A.M.D., et al. (2020):** Eight weeks of treatment with nandrolone decanoate in female rats promotes disruption in the redox homeostasis and impaired renal function. *Life Sci*, 242:117227.
- Liu, J.D. and Wu, Y.Q. (2019):** Anabolic-androgenic steroids and cardiovascular risk. *Chinese Medical Journal*, 132 (18): 2229-2236.
- Lopes, R.A.M.; Neves, K.B.; Pestana, C.R.; Queiroz, A.L.; Zanotto, C.Z.; Chignalia, A.Z. & Tostes, R.C. (2014):** Testosterone induces apoptosis in vascular smooth muscle cells via extrinsic apoptotic pathway with mitochondria-generated reactive oxygen species involvement. *American Journal of Physiology-Heart and Circulatory Physiology*, 306(11), H1485-H1494.
- Mabrouki, L.; Rjeibi, I.; Taleb, J. & Zourgui, L. (2020):** Cardiac Ameliorative Effect of Moringa Oleifera Leaf Extract in High-Fat Diet-Induced Obesity in Rat Model. *Biomed. Res. Int*, Volume 2020, Article ID 6583603, 10 pages.
- Magalhães, S. C.; de Oliveira, K. A.; Freiras, P. A.; Gomes, M. D. M.; Pereira, L. M.; Boa, L. F. & de Oliveira, A. C. (2020):** High-dose Nandrolone Decanoate induces oxidative stress and inflammation in retroperitoneal adipose tissue of male rats. *The Journal of Steroid Biochemistry and Molecular Biology*, 203, 105728
- Meador, B.M.; Krzyszton, C.P.; Johnson, R.W. and Huey, K.A. (2008):** Effects of IL-10 and age on IL-6, IL-1beta, and TNF-alpha responses in mouse skeletal and cardiac muscle to an acute inflammatory insult. *J Appl Physiol*;104(4):991-7.
- Melhem, A. J. Jr.; Araújo, A. C.; Figueiredo, F. N. C. and Figueiredo, D. L. A. (2020):** Acute Myocardial Infarction in a Young Bodybuilder: A Case Report and Review of the Literature. *Am J Case Rep*. 21: e924796-1-e924796-8.
- Miltonprabu, S. and Thangapandiyam, S. (2015):** Epigallocatechin gallate potentially attenuates Fluoride induced oxidative stress mediated cardiotoxicity and dyslipidemia in rats. *Journal of Trace Elements of Medicine & Biology*, 29:321-335.
- Misra, S.; Srivastava, M. and Srivastava, M. (2014):** "Evaluation of the anti-diarrheal potential of Moringa oleifera (Lam.) leaves," *Journal of Pharmacognosy and Phytochemistry*, vol. 2, no. 5, pp. 43-46.
- Mohamed, H.Z.E. & Mohamed, H.K. (2022):** Histological and immunohistochemical studies of the effects of administration of anabolic androgenic steroids alone and in concomitant with training exercise on the adult male rats skeletal muscles. *Egyptian Journal of Histology*, 45(1), 36-49
- Mohammed, E. T.; Radi, A. M.; Aleya, L. and Abdel-Daim, M.M. (2020):** Cynara scolymus leaves extract alleviates nandrolone decanoate-induced alterations in testicular function and sperm quality in albino rats. *Environmental Science and Pollution Research*., 27, pages5009-5017

- Mullen, C.; Whalley, B.J.; Schifano, F.; Baker, J.S. (2020):** Anabolic androgenic steroid abuse in the United Kingdom: An update. *Br. J. Pharmacol*, 177, 2180–2198.
- Müller B. M.; Sylvén, C.; Rasmanis, G. et al. (2000):** "Evaluation of a point-of-care system for the quantitative determination of troponin T and myoglobin," *Clinical Chemistry and Laboratory Medicine*, vol. 38, no. 6, pp. 567–574.
- Mumtaz, M.Z.; Kausar, F.; Hassan, M.; Javaid, S.; Malik, A. (2021):** Anticancer activities of phenolic compounds from *Moringa oleifera* leaves: in vitro and silico mechanistic study. *Beni-Suef University Journal of Basic and Applied Sciences*, 10-12.
- Osonuga, I.O.; Ogunlade, A. A.; Olalekan, S.O.; Okwbule, B.O. and Olukade, B.A. (2020):** The effect of aqueous leaves extract of *moringa oleifera* on testosterone and prolactin level in adult male Wistar rats (*Rattus norvegicus*). *Nigerian Journal of Scientific Research*, 19 (3):175-180.
- Panda, S.; Kar, A.; Sharma, P.; Sharma, A. (2013):** Cardioprotective potential of N, α -l-rhamnopyranosyl vincosamide, an indole alkaloid, isolated from the leaves of *Moringa oleifera* in isoproterenol-induced cardiotoxic rats: In vivo and in vitro studies. *Bioorganic & Medicinal Chemistry Letters*, 23, 959–962.
- Patanè, F.G.; Liberto, A.; Maglito, A.N.M.; Malandrino, P.; Esposito, M.; Amico, F.; Cocimano, G.; Li Rosi, G.; Condorelli, D.; Di Nunno, N.; et al. (2020):** Nandrolone Decanoate: Use, Abuse and Side Effects. *Medicina* 2020, 56, 606.
- Rosca, A.E.; Stancu, C.S.; Badiu, C.; Popescu, B.O.; Mirica, R.; Constantin Căruntu, C.; Gologan, S.; Voiculescu, S.E. and Zagrean, A.M. (2019):** Lipid Profile Changes Induced by Chronic Administration of Anabolic Androgenic Steroids and Taurine in Rats. *Medicina.*, 55, 540.
- Ruiz-Meana, M.; Minguet, M.; Bou-Teen, D.; Miro-Casas, E.; Castans, C.; Castellano, J. et al. (2019):** Ryanodine receptor glycation favors mitochondrial damage in the senescent heart. *Circulation* 139, 949–964.
- Saddick, S.Y. (2021)** Effect of Nandrolone decanoate induced-oxidative stress on rat testes, prostate, and seminal vesicle: Biochemical, morphometric and histopathological studies. *Saudi journal of biological sciences*, 28(1):196–203.
- Sadowska-Krepa, E.; Klapcińska, B.; Jagsz, S.; Sobczak, A.; Chrapusta, S.J.; Chalimoniuk, M. et al. (2011):** High-Dose Testosterone Propionate Treatment Reverses the Effects of Endurance Training on Myocardial Antioxidant Defenses in Adolescent Male Rats. *Cardiovasc Toxicol*, 11: 118-127.
- Salem, N.A. & Alnahdi, H.S. (2020):** The impact of nandrolone decanoate abuse on experimental animal model: Hormonal and biochemical assessment. *Steroids*, 153: 108526.
- Shaito, A.; Thuan, D. T. B.; Phu, H. T.; Nguyen, T. H. D.; Hasan, H.; Halabi, S. et al. (2020):** Herbal Medicine for Cardiovascular Diseases: Efficacy, Mechanisms, and Safety. *Front. Pharmacol.* 11 (April), 422–432.
- Soliman, M.E.S.; El-saify, G.H.; Khair, N.S.B.; Soliman, M.A.M., & AboHabsa, S.S. (2017):** Effect of Nandrolone on Rat Cardiac Muscle and the Possible Protective Role of Vitamin E: A Light & Electron Microscopic Study. *J Am Sci*, 13(4), 24-36.
- Sreeja, M.; Jayasri, P.; Keerthi, N.; Yeshashwini, J. & Praveen, J. (2021):** *Moringa oleifera*: A review on nutritive importance and its potential use as nutraceutical plant. *Journal of Medicinal Plants*, 9(2), 15-7.
- Sretenovic, J.; Zivkovic, V.; Srejovic, I.; Ajdzanovic, V.; Ristic, N.; Trifunovic, M. et al. (2020):** Immunohistomorphometric and hormonal analysis of the pituitary gonadotropic cells after application of the nandrolone decanoate and

- swimming training in adult male rats. *Microsc Microanal.*, 26:699–707.
- Sretenovic, J.; Zivkovic, V.; Srejavic, I.; Pantovic, S.; Jovic, J.J.; Nikolic, M. et al. (2022):** Nandrolone Decanoate and Swimming Affects Cardiodynamic and Morphometric Parameters in the Isolated Rat Heart. *Life (Basel, Switzerland)*, 12(8).
- Thomas, T. P. & Grisanti L. A. (2020):** The dynamic interplay between cardiac inflammation and fibrosis. *Frontiers in Physiology*, 11, 529075.
- Tofighi, A.; Shirpoor, M.; Ansari, M.H.; Shirpoor, A. and Zerehpooosh, M. (2017):** The effect of nandrolone treatment with and without enforced swimming on histological and biochemical changes in the heart and coronary artery of male rats. *Anatol J Cardiol*, 17(3):176-83.
- Tousson, E.; Alm-Eldeen, A. and El-Moghazy, M. (2011):** p53 and Bcl-2 expression in response to boldenone induced liver cells injury. *Toxicol. Ind. Health*, 27: 711-718
- Ulla, A.; Mohamed, M.K.; Sikder, B.; Rahman, A.F.M.; Sumi, F.A.; Hossain, M. et al. (2017):** Coenzyme Q10 prevents oxidative stress and fibrosis in isoprenaline induced cardiac remodeling in aged rats. *BMC Pharmacology and Toxicology*, 18(1), 1-10.
- Vorona, E. and Nieschlag, E. (2018):** Adverse effects of doping with anabolic androgenic steroids in competitive athletics, recreational sports, and bodybuilding. *Minerva Endocrinol.*, 43:476-488.
- Whitaker, J. F. (1969):** “A general colorimetric procedure for the estimation of enzymes which are linked to the NADH/ NAD⁺ system,” *Clinica Chimica Acta*, vol. 24, no. 1, pp. 23–37, 1969.
- Zakaria, N.; Khalil, S.R.; Awad, A.; Khairy, G.M. (2018):** Quercetin reverses altered energy metabolism in the heart of rats receiving Adriamycin chemotherapy. *Cardiovascular Toxicology*, 18,109–119.
- Zilva, J. F. and Pannall, P. R. (1985):** “Clinical chemistry in diagnosis and treatment,” Lloyd-Luke, London, 1985.

الملخص العربي

التأثيرات القلبية لمستخلص المورينجا اوليفيرا على التغيرات الكيميائية والألتهابات النسيجية و التركيب الدقيق في السمية القلبية المستحثة بالناندرولون ديكانوات في ذكور الجرذان البيضاء البالغة

هند رجب موسى^١ عبير على الديب^٢ على محمد على^٣

^١ قسم الأمبريولوجى والتشريح ، ^٢ قسم الفارماكولوجى .كلية الطب البشرى.جامعة بنها.

المقدمة: يعتبر الناندرولون ديكانوات احد الستيرويد المنشطة وقد تم تسجيل بعض الآثار السامة على القلب (عدم انتظام ضربات القلب، واحتشاء عضله القلب الحاد ووالموت المفاجئ). مستخلص المورينجا اوليفيرا هو مستخلص عشبي يستخدم لعلاج الأمراض المختلفة بسبب تأثيره المضاد للأكسدة.

الهدف من العمل: هدفت هذه الدراسة إلى التحقق من فاعلية مستخلص المورينجا اوليفيرا كعامل وقائي ضد السمية القلبية التي يسببها الناندرولون ديكانوات.

المواد وطرق البحث: تم اجراء تجربته على ٣٢ فأر مقسمين الى اربع مجموعات كل مجموعه تحتوى على ٨ فئران. المجموعة الأولى (المجموعه الضابطة): تم اعطائها زيت السمسم تحت الجلد كل اسبوع لمدة ٤ اسابيع. المجموعة الثانية (مستخلص المورينجا اوليفيرا): تم اعطائها المورينجا ٤٠٠ مجم/كجم/اليوم لمدة ٤ اسابيع عن طريق الفم. المجموعة الثالثة (الناندرولون ديكانوات): تم اعطائها الناندرولون ٢٠ مجم/كجم/اسبوع لمدة ٤ اسابيع تحت الجلد. المجموعة الرابعة (مستخلص المورينجا+الناندرولون ديكانوات): تم اعطاء الفئران المورينجا والناندرولون بنفس الجرعات السابقه. وفي نهاية الدراسة تم اخذ عينات الدم لقياس انزيمات القلب ثم ذبح الفئران واخذ عينات القلب لقياس نسبة معاملات الأكسدة (لمالونديألدهيد و غلوتاثيون مُخْتَزَل و نشاط أنزيم الكاتالاز و نشاط فوق اكسيد الادموتاز) ومعاملات الألتهاب (عامل نخر الورم - ألفا وانترلوكين ٦ وانترلوكين ١٠). و تم إخضاع العينات القلبية للفحص بالميكروسكوب الضوئي وداسه كيميائية مناعية باستخدام الأجسام المضادة ل-P53 والأجسام المضادة لكونيكسين43 وفحص الميكروسكوب الإلكتروني ثم أجريت دراسات قياسية وإحصائية.

النتائج: اظهرت النتائج ان الفئران التى تم اعطائها الناندرولون ديكانوات ارتفاع فى نسبة انزيمات القلب و نسبة معاملات الأكسده (المالوندي الدهيدو) و معاملات الألتهاب (عامل نخر الورم - ألفا و إنترلوكين ٦) وانخفاض نسبة مضادات الأكسده (غلوتاثيون مُخْتَزَل و نشاط أنزيم الكاتالاز و نشاط فوق اكسيد الادموتاز) و انخفاض نسبة إنترلوكين ١٠. وأوضح فحص الميكروسكوب الألكترونى اتساع فى الغلاف الخارجى للعضله وارتشاح ألتهابى وتموج وتمزق الألياف وترسب ألياف الكولاجين بين الألياف المتقطعه. وأيضا زياده تعبير بروتين ٥٣ P فى النواه وتعبير كونيكسين ٤٣ زبالفحص الدقيق تبين ظهور تقطع فى الأليافو إتساع فى الشبكة ألتدوبالزمية الملساءو تشوه القرص البينى. وقد أظهرت نتائج مجموعه التي سبق إعطائها (مستخلص المورينجا+الناندرولون ديكانوات) تحسن واضح فى تركيب عضله القلب الدقيق و أيضا انخفاض فى نسبة انزيمات القلب و نسبة معاملات الأكسده (المالوندي الدهيدو) و معاملات الألتهاب (عامل نخر الورم - ألفا و إنترلوكين ٦) و ارتفاع نسبة مضادات الأكسده (غلوتاثيون مُخْتَزَل و نشاط أنزيم الكاتالاز و نشاط فوق اكسيد الادموتاز) و ارتفاع نسبة إنترلوكين ١٠

الأستنتاج

تشير هذه النتائج ان مستخلص المورنجا اوليفيرا يخفف من التأثيرات السامة للقلب التي يسببها الناندرولون ديكانوات في الجرذان من خلال التأثيرات المضادة للالتهابات ومضادات الأكسدة ومضادات موت الخلايا المبرمج.