

TOXICOLOGICAL EFFECTS OF THE ANTIRETROVIRAL DRUG (NEVIRAPINE) ON MALE ALBINO RATS: A GENETIC & HISTOPATHOLOGICAL STUDY

Yasmina B. Abd El-magid*, Amina A. Farag* and Mohamed A. El-Shishtawy*

*Forensic Medicine & Clinical Toxicology Department, Faculty of Medicine, Benha University, Egypt

Corresponding author: Yasmina B. Abd El-magid, Forensic Medicine & Clinical Toxicology Department, Faculty of Medicine, Benha University, Egypt, yasmeena2014@yahoo.com, +2 01093330322

ABSTRACT

Objectives: Nevirapine (NVP) is a non-nucleoside reverse transcriptase inhibitor used in the treatment of HIV infections. It has been reported that NVP has a toxic effect on the liver, kidney and male reproductive system. This study was designed to assess the NVP toxic effects on these tissues (liver, kidney and testis) and its possible genotoxic and mutagenic effects. **Methodology:** Forty adult male albino rats were divided into 4 groups (10 rats each): (A) negative control group, (B) positive control group received 1ml/ day of corn oil, (C) NVP1 treated group received 3.6mg (loading dose) of the drug for 2 weeks and (D) NVP2 treated group received the loading dose of the drug for 2 weeks then 7.2 mg (maintenance dose) for 2 weeks more. **Results:** The results of present study revealed the followings: NVP did not alter the body weight gain or kidney weight, but it increased liver weight in (group C) and decreased testis weight in (group D). NVP caused a high significant increase of liver function tests (serum aspartate transferase, alanine transaminase, alkaline phosphatase and total bilirubin), a high significant decrease in hormonal levels of testes (testosterone, FSH and LH) and no significant difference on kidney function tests (urea and creatinine). Histopathological changes in liver and testis in NVP-treated groups were observed as compared to control groups. Comet assay showed that NVP caused a highly significant damage in blood cells in a dose dependent fashion. This result suggests for the first time that this drug might induce genotoxicity in the whole blood. **Conclusion:** oral exposure of adult albino rats to NVP at a human therapeutic dose daily for 4 weeks leads to toxic effects on liver and damaging effect on male reproductive system in addition to the genotoxicity.

Keywords: Nevirapine, hepatotoxicity, testicular toxicity, comet, genotoxicity.

INTRODUCTION

Nevirapine (NVP) is a first-generation of non nucleoside reverse transcriptase inhibitors (NNRTIs), cheap and widely available around the world. It has several advantageous characteristics and little adverse CNS events when compared with efavirenz (NNRTI), fewer drug interactions than protease inhibitors (PIs) and its bioavailability is not affected by food (Bieńczyk et al., 2017; Čolic et al., 2015).

This antiretroviral therapy (ART) is capable of reducing the quantity of HIV and

Nevirapine is usually used as a part of the extremely active antiretroviral therapy (HAART) in resource-limited settings. Currently, it remains one in every of the foremost prescribed ARVDs in developing countries, to stop vertical transmission (mother-to-child) once utilized in combination therapy (Lockman et al., 2007).

improving the functioning of the immune system, but unfortunately, extended use will

trigger many adverse effects such as rash, hypersensitivity syndrome, and hepatotoxicity (de Maat et al., 2007; Roca, 2009).

The most common adverse effects related to presently used ART regimens are anaemia, itching, skin rash, elevated triglycerides, peripheral neuropathy, thrombocytopenia, pancreatitis and most dangerous is hepatotoxicity (Rather et al., 2013).

Hepatotoxicity associated with NVP was identified by 3- fold increase greater than the upper normal values of liver enzymes; serum ALT and/ or serum AST (Cabello et al., 2015).

Renal disease before start of HAART is quite common in HIV infected patients (Banda et al., 2010). However, long term exposure to HAART may also be associated with significant renal toxicity (Manosuthi et al., 2010). Renal dysfunction is mainly attributed to Tenofovir (NtRTIs) and PIs, but very few studies have been done to determine the contribution of other antiretroviral agents (Makori et al., 2015).

The adverse effects of HAART on fertility especially in growing societies have become a significant cause for attention. As HIV is most prevalent among people of reproductive age, about one-third of who want to have kids, reproductive desires have emerged as clinically important in people living with HIV/AIDS (PLWHAs) (Kushnir & Lewis, 2011).

According to de Oliveira et al. (2014), acute exposure of ordinary mice to NVP did not trigger important degrees of genotoxicity or mutagenicity (de Oliveira et al., 2014).

AIM OF THE WORK

The aim of this study is to assess the toxic effects of nevirapine (non-nucleoside reverse transcriptase inhibitor) on different

tissues (liver, kidney and testis) and to study its genotoxic and mutagenic effects on male adult albino rats.

MATERIALS AND METHODS

I- Materials:

A- Chemicals:

• Nevirapine (Viramune) as tablets (CAS number: 129618-40-2) was purchased by Boehringer Ingelheim (France).

• Corn oil as a liquid of purity \pm 99% (CAS number 8001-30-7) was purchased from Sigma- Aldrich (ST Louis, Missouri, USA).

B- Animals:

This work was carried out on forty male adult albino rats weighing between 180gm and 200gm. All rats were allowed for one week of adaptation (taking food & water without any medications) in their new environment at Anatomy Department, Faculty of Medicine, Benha University.

The local Ethical Committee, Benha Faculty of Medicine, recognized this study.

C- Animal groups

At the beginning of the study, randomization was done and animals were categorized into four groups (10/ group):

Group (A) male negative control group (10 male rats): lifted without intervention to record the basic parameters, with free access to food and water for 4 weeks.

Group (B) male positive control group (10 male rats): each rat received 1ml/ day of corn oil by oral gavage for 4 weeks according to (Adaramoye et al., 2013).

Group (C) NVP1 male treated group (10 male rats): each rat received the loading dose of NVP once daily for 14

days. Rat loading dose= $200\text{mg} \times 0.018 = 3.6\text{mg}/200\text{g}$ according to **Paget and Barnes (1964)**.

Group (D) NVP2 male treated group (10 male rats): each rat received the loading dose of NVP ($3.6\text{mg}/200\text{g}$) once daily for 14 days. Then, each rat received the maintenance dose of NVP once daily for another 14 day. Rat maintenance dose= $400\text{mg} \times 0.018 = 7.2\text{mg}/200\text{g}$ according to **Paget and Barnes (1964)**.

Each rat received NVP orally, via appropriate sized metallic cannula dressed with plastic cover (oral gavage) that not exceeds the tip by 2- 3 ml to prevent injury of the esophagus.

Sample collection:

After the end of the experimental time for each group, rats were anaesthetized with ether inhalation, the abdominal cavity was opened, and blood samples were collected from heart and prepared for biochemical measurements and comet assay. The liver, kidney and testis were collected and putted in 10% formalin to do the histopathological study.

Methods (study parameters):

1. Body and relative organs weight, general health and gross behavior of the animals:

All animals were observed daily for general clinical and behavioral changes. The clinical response and behavior were monitored for 1 h after drug administration and periodically for 24 h. The behavior was assessed by observing the animals' social contact with littermates in the cage. The macroscopic appearance of animals was evaluated by checking the animals' fur for cutaneous reactions (**de Oliveira et al., 2014**).

Also, animals' body weights were measured on the first day before treatment, at two weeks and four weeks later at the

end of intervention. Individual organ weight was measured using sensitive electronic balance, after scarification, the organs of each rat were weighed separately and the relative organ weight was calculated using the equation of (organ weight/ body weight x 100).

2. Biochemical study:

Liver enzymes:

Spectrophotometrically, AST, ALT, alkaline phosphatase (ALP) and total bilirubin levels were measured using the commercial test of each with spinlab(Spinreact company), Spain.

Kidney enzymes:

Urea and creatinine levels were calculated spectrophotometrically using the commercial test of urea with spin lab (Spinreact company), Spain.

Hormones:

Using Enzyme Linked Fluorescent Assay, Testosterone, Follicle-Stimulating Hormone (FSH) and Luteinizing Hormone (LH) levels were detected, using the commercial kits VIDAS for each (BIOMERIEUX Company, France) using VIDAS apparatus (BIOMERIEUX Company, France). **Histopathological study:**

After staining with Haematoxylin and Eosin (H&E), sections from liver, kidney, and testis were studied by light microscope. **Comet assay:**

Sample preparation

Dhawan et al. (2003) altered a traditional protocol for sample preparing and comet assay analysis. After sample slides preparation, the slides were dipped into lysis solution at 4°C for 1 day. Subsequently, the slides were placed at room temperature for 20 minutes in an electrophoresis buffer to generate single stranded DNA.

Electrophoresis was then linked to a new, cold electrophoresis buffer at 300 mA and

19 V in a horizontal electrophoresis platform for 20 minutes. Then, neutralization of the gel is by rinsing the slides with suitable buffer (Tris pH 7.5) for 5 min three times for 5 min. / each. Before staining slides were dehydrated by immersing in absolute ethanol for 5min. The slides were stained for 10 minutes with 10% ethidium-bromide.

The slides were evaluated using the prepared Leitz Orthoplanepi fluorescence microscope with a 515-560 nm excitation filter. 100 randomly selected cells, respectively, were photographed and scanned in every irradiation dose. Analysis was done by image analysis using comet score

Statistical analysis:

SPSS version 16 software (SpssInc, Chicago, ILL Company) was used to analyse and tabulate the gathered data. Data was displayed as mean deviation and range \pm standard. They have been screened for normality with the Shapiro-Wilks test assuming normality $t P > 0.05$, ANOVA test was used to analyze difference between groups regarding normally distributed variables, while non parametric ones were analyzed using Kruskal Wallis (KW) test. Significant ANOVA or KruskalWallis tests were followed by post hoc multiple comparisons using Bonferroni tests to detect the significant pairs.

According to Greenberg et al. (1996) and Khothari (2004), the accepted standard of meaning in this job was indicated at 0.05 (P value > 0.05 was considered insignificant) studied groups at the start of the study, at the end of the 2nd week and 4th week of

The only statistical change a highly significant increase in mean values of relative liver weight in NVP1 treated group as compared to the control groups and NVP2 treated group. There is no statistically significant difference between

software. The comet cell characters that were chosen were tiny heads and big fan-like tails.

The duration of DNA migration (tail length) from the middle of the nucleus to the tail end was evaluated in (μm) for each cell. The proportion of DNA in the tail was determined by evaluating the cells' complete intensity (fluorescence), which was taken as 100%, and determining which proportion of that complete intensity corresponded to the intensity measured in the tail only. The tail moment was calculated as: (tail length X proportion of migrated DNA/100) expressed in arbitrary units (Końca et al., 2003).

Significant, $P < 0.05$ was regarded important and $P < 0.001$ was regarded extremely important).

RESULTS

I- Observations during the study:

A) Behavioral changes:

There were some behavioral changes that had been observed in nevirapine (NVP1) and (NVP2) treated groups. These changes were isolated from others and lack of movement, which were transient and occurred approximately 1 week after beginning of the study. **Dermal changes:**

Skin rashes were noticed in rats of both treated groups. These rashes gradually increased and lasted to the end of the study.

II- Weight of the body and organs:

No statistical significant ($p > 0.05$) difference are showed in all

drug administration regarding body weights (Table 1).

NVP2 treated group and the control groups. Also, there is a highly significant decrease in mean values of relative testis weight in NVP2 treated group as compared to the control groups and NVP1 treated group. But, there is a non statistical significant

between the four groups regarding mean values of relative kidney weight (**Table 2**).

III- **Biochemical study:**

A highly significant increase is observed in mean values of AST, ALT, ALP and total bilirubin levels in NVP1 and NVP2 treated groups as compared to the control groups. Also, there is a highly significant difference between NVP1 and NVP2 treated groups regarding these parameters (**Table 3**).

No statistically significant ($p > 0.05$) differences are shown in all studied groups regarding mean values of urea level and creatinine level (**Table 4**).

Regarding the hormonal assessment, there is a highly significant decrease in mean values of FSH, LH and testosterone levels in NVP1 and NVP2 treated groups as compared to the control groups. There is no statistical significance between the treated group according to the same parameters (**Table 5**).

IV- **Histopathological study:**

Histopathological examination of the liver of the NVP1 treated group showed changes in liver histopathology as central vein congestion, fatty degenerations with singent ring appearance, hydropic degeneration. These changes aggravated in NVP2 treated group with appearance of marked necrosis and major distortion of architecture. There were no histopathological changes on examination of NVP1 and NVP2 treated group kidneys. Testicular tissue examination, however, disclosed degeneration of seminiferous tubules (ST), spermatocyte necrosis and defoliation of many spermatocytes into ST lumen, which worsened in NVP2 compared to NVP1 (**fig. 1**).

V- **Single cell electrophoresis (comet assay):**

Tail length and moment mean values were significantly higher among the treated group than the controls. And there

is no statistical significance between both treated groups (**Table 6**).

In both treated groups, the comet assay showed a substantial rise in tail length relative to controls. NVP2 treated group had increasing tail length as compared to tail length of NVP1 treated group which was indicated more severe DNA damage as shown in (**fig 2**).

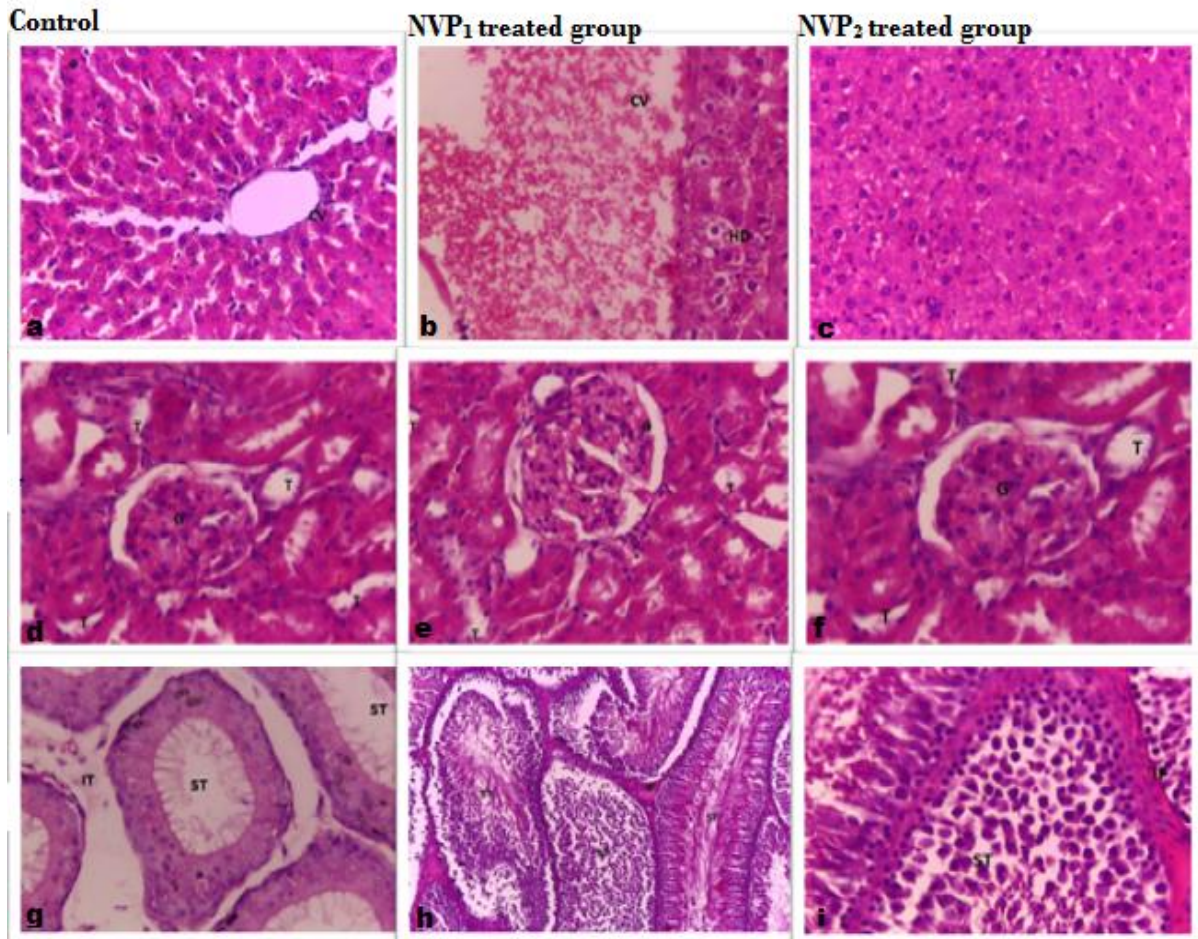


Fig. 1: (a) a photomicrograph of a section in rat's liver prepared from a control rat showing normal architecture, normal diameter central veins (CV) and sinusoids. (b) a photomicrograph of a section in rat's liver prepared from NVP1 treated group showing dilated central veins (CV) with congestion, hydropic degeneration (HD), fatty degeneration (FD). (c) a photomicrograph of a section in rat's liver prepared from NVP2 treated group showing major lose of hepatic architecture with marked necrosis. (d) A photomicrograph of a section in rat's kidney prepared from a control group showing normal architecture with normal tubules (T) and glomeruli (G). (e) a photomicrograph of a section in rat's kidney prepared from NVP1 treated group showing normal architecture with normal tubules (T) and glomeruli (G). (f) a photomicrograph of a section in rat's kidney prepared from NVP2 treated group showing normal architecture with normal tubules (T) and glomeruli (G). (g) a photomicrograph of a section in rat's testis prepared from a control rat showing normal architecture with well-arranged seminiferous tubule (ST), normal interstitial tissues (IT) and cells. (h) a photomicrograph of a section in rat's testis prepared from NVP1 treated group showing disruption of ST, necrosis of spermatocytes, defoliation of many spermatocytes into lumen of the ST and interstitial fibrosis (IF). (i) a photomicrograph of a section in rat's testis prepared from NVP2 treated group showing marked lose of testicular tissue architecture, extensive disruption of ST, necrosis of spermatocytes, defoliation of many spermatocytes into lumen of the ST and interstitial fibrosis (IF) (H & E x400).

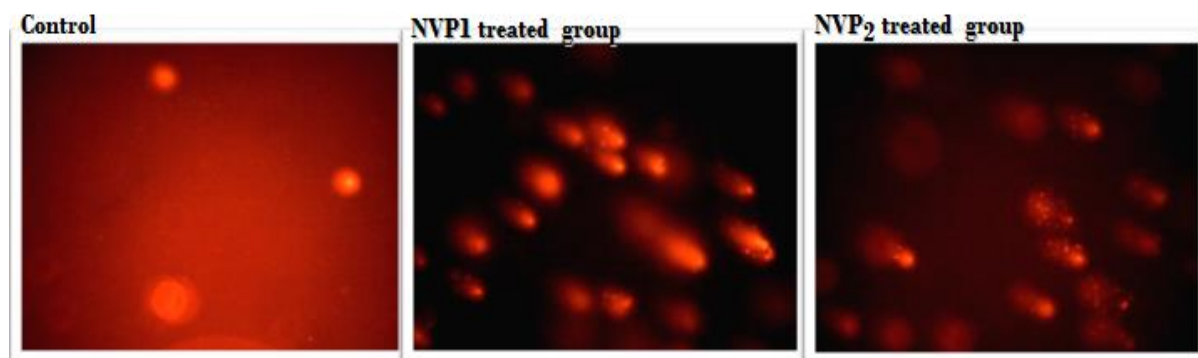


Fig (2): Comet images of blood cells from control group, NVP1 treated and NVP2 treated groups. Treatment with NVP increased the DNA damage in a dose dependent fashion.

Table (1): Comparing the studied groups regarding mean values of body weight at different intervals.

Groups	Bodyweight before treatment (gm)	Bodyweight at the end of 2nd week of treatment (gm)	Bodyweight at the end of 4th week of treatment (gm)
Group A (-ve control) (n= 10)	185.2±10.54	203.8±15.13	219.2±16.07
Group B (+ve control) (n= 10)	184.6±3.92	207.0±7.08	221.2±6.51
Group C (NVP1 treated group) (n= 10)	190.8±7.84	202.4±1.42	214.6±7.73
Group D (NVP2 treated group) (n= 10)	191.8±9.17	202.0±8.08	—
Test	ANOVA (2.04)	KW (4.34)	KW (3.27)
P value	0.126	0.227	0.19

*= significant in comparison with C

†= significant in comparison with D

Table (2): Comparing the studied groups regarding mean values of relative organ weight.

Groups	Relative liver weight (gm)	Relative kidney weight (gm)	Relative testis weight (gm)
Group A (-ve control) (n= 10)	2.27±0.23*	1.48±0.168	0.96±0.093†
Group B (+ve control) (n= 10)	2.26±0.16*	1.39±0.097	0.98±0.098†
Group C (NVP1 treated group) (n= 10)	2.56±0.01	1.49±0.055	0.92±0.041†
Group D (NVP2 treated group) (n= 10)	2.30±0.11*	1.44±0.085	0.81±0.053
KWT	17.02	6.24	16.1
P value	0.001	0.227	0.001

Table (3): Comparing the studied groups regarding mean values of AST, ALT, ALP and total bilirubin levels.

Groups	AST (U/L)	ALT (U/L)	ALP (IU/L)	T.bilirubin (mg/dl)
Group A (-ve control) (n= 10)	100.8±23.14	36.4±7.56	138.4±42.8	0.38±0.07
Group B (+ve control) (n= 10)	102.8±21.7	34.8±16.69	100.8±46.4	0.52±0.13
Group C (NVP1 treated group) (n= 10)	198.1±13.81*†	72.3±28.41* ‡	690.7±199.6* ‡	0.66±0.05†
Group D (NVP2 treated group) (n= 10)	139.6±22.47*†‡	69.3±8.85*† ‡	391.8±51.7*† ‡	0.80±0.18*†
KWT	28.4	22.3	34.0	26.6
P value	0.001	0.001	0.001	0.001

*= significant in comparison with A

†= significant in comparison with B

‡=significant in comparison with C

Table (4): Comparing the studied groups regarding mean values of urea and creatinine levels

Groups	Urea (mg/dl)	Creatinine (mg/dl)
Group A (-ve control) (n= 10)	26.8±3.48	0.48±0.07
Group B (+ve control) (n= 10)	27.6±6.61	0.50±0.09
Group C (NVP1 treated group) (n= 10)	33.2±6.94	0.62±0.22
Group D (NVP2 treated group) (n= 10)	28.6±4.35	0.72±0.43
KWT	5.11	5.14
P value	0.164	0.16

Table (5): Comparing the studied groups regarding mean values of FSH, LH and testosterone level.

Groups	FSH (IU/mL)	LH (mIU/mL)	Testosterone (ng/dl)
Group A (-ve control) (n= 10)	10.26±1.76	6.84±0.51	7.42±0.87
Group B (+ve control) (n= 10)	9.96±2.45	5.78±0.98	6.66±0.73
Group C (NVP1 treated group) (n= 10)	0.16±0.03*†	0.12±0.05*†	0.54±0.37*†
Group D (NVP2 treated group) (n= 10)	0.03±0.02*†	0.06±0.01*†	0.90±0.29*†
KWT	33.2	32.8	31.6
P value	0.001	0.001	0.001

*= significant in comparison with A

†= significant in comparison with B

Table (6): Comparing the studied groups regarding mean values of tail length and tail moment.

Groups	Tail length (µm)	Tail moment
Group A (-ve control) (n= 10)	2.58±0.58	0.27±0.077
Group B (+ve control) (n= 10)	2.58±0.58	0.25±0.075
Group C (NVP1 treated group) (n= 10)	9.89±1.59*†	0.44±0.152*†
Group D (NVP2 treated group) (n= 10)	13.33±5.77*†	0.46±0.156*†
KWT	29.7	30.1
P value	0.001	0.001

*= significant in comparison with A

†= significant in comparison with B

DISCUSSION

Nevirapine is the first line drug for HIV infection from the category of NNRTI (Mohamed et al., 2019). Bioavailability of NVP in rats is more than 90% and it is absorbed by the small intestine and colon as that observed in humans, which makes the rat a perfect animal model for performing studies on the absorption of NVP (Usach & Peris, 2011).

The present work experimentally was studied on male adult albino rats, aimed to assess the toxic effects of NVP on (liver,

kidney & testis) and to investigate the genotoxic effect of the drug.

Results of this study showed behavioral changes that had been observed in NVP1 and NVP2 treated groups. These changes were fatigue and lack of movement of some rats, which were transient and occurred approximately 1 week after beginning the study.

By comparison, de Oliveira et al. (2014)'s research showed that the administration of NVP did not result in any modifications in the overall conduct (such as spasms, muscle tremors, salivation or sedation) on the rats being handled. This contrast might

be due to the different dose used in their study (3.3 mg/kg single dose in 24 hours).

According to **Licitud et al. (2015)** study, which agree with the current work, these changes could be explained by presence of muscle, joint aches or general malaise which occurred as side effects of the drug.

During the current study dermal changes were noticed. These changes were skin rashes which appeared from the 7th day, gradually increased and persistent till the end of the study among rats of both treated groups.

These results are in agreement with **Hall and Macgregor (2007)** who suggested that patients administrated NVP produced skin rash would have higher blood levels of a major metabolite of nevirapine 12- hydroxynevirapine (12-OHNVP) (**Riska et al., 1999**). That explained by **Shenton et al. (2005)** who stated that immune-mediated reaction to the metabolites of NVP was found, Pre-treatment with immunosuppressants (cyclosporine and tacrolimus) banned rash and even resulted in rash resolution during NVP therapy. **The present study demonstrated a non significant (P > 0.05) difference between all studied groups regarding bodyweights before, at the end of 2nd week and at the end of the study (4th week).**

In agreement with these results, **Elias and Bonsome (2017), Cortez et al. (2014) and Adaramoye et al. (2012)** found that administration of NVP did not significantly ($p > 0.05$) alter the body weight gain.

The rats were observed no failure to eat or drink during the period of the experiment and that explains the cause of no weight loss.

This research showed a very important rise in relative liver weight mean values in the treated NVP₁ group compared to the other groups (control groups and treated NVP₂ group).

These findings were in harmony with **Adaramoye et al. (2012)** who reported tha

t NVP weight / day administration in rats induced a substantial rise ($p < 0.05$) in relative liver weight.²⁷

On the other hand, **Elias and Bonsome (2017)** noted that 14day therapy with doses (4, 8, 16, 32) mg / kg / day of NVP had no important ($p > 0.05$) impacts on relative liver weights compared to control.

Increase relative liver weight of NVP₁ treated rats might be due to the hydropic and fatty degenerations (**Hall et al., 2012**). These were observed by histopathological examination in the current study.

The current study showed a non statistical significant difference between the four groups regarding relative kidney weight. The average relative kidney weights of -ve control, +ve control, NVP₁ and NVP₂ treated groups were 1.48, 1.39, 1.49 and 1.44 gm respectively.

Elias and Bonsome (2017) and Adaramoye et al. (2012) coincided with the current results and reported that treatment with NVP did not result in significant ($p > 0.05$) effects on the relative kidney weights when compared to control group.

However, **Offor et al. (2017)** opposed the current results and reported a significant increase in the kidney body weight ratio ($p < 0.001$) for 56 days in the NVP treated group at a dose of 1.54 mg / kg.

That result might be assured by that there was no biochemical or histopathological changes of rats' kidneys. So, the difference between **Offor et al. (2017)** study and the current study might be due to the duration which it were 8 weeks in their study and 4 weeks in the present study.

The present study showed a highly significant decrease in the mean values of relative testis weight in NVP₂ treated group as compared to the control groups as well as to NVP₁ treated group. There was also no statistically significant distinction between the group being handled

with NVP1 and the control groups. This observation was correlated with the totally damaged testis which seen in the histopathological examination.

There was a harmony between these results and those of **Ajayi et al. (2016)** who reported that administration of NVP decreased the relative testis weight in treated rats. They explained that the decrease in relative testis weight in their study might be an indication of change in state of the body androgen (**Biswas et al., 2001**).

In contrast, **Adaramoye et al. (2013)** reported that administration of NVP did not significantly ($p > 0.05$) alter the relative testis weight.

A highly significant increase in mean values of serum AST, ALT, ALP and total bilirubin levels were showed in NVP1 and NVP2 treated groups as compared to the control groups. Also, there is a highly significant increase in NVP1 compared to NVP2 treated groups.

Partially agreed with the present results by **Olapido et al. (2016)**. They discovered that NVP administration resulted in a substantial rise in mean values of AST and ALT relative to control but, compared to control, a reduction in mean values of ALP mean value. **Umar et al. (2008)** research findings also found that NVP administration resulted in important rises ($p < 0.05$) in AST and ALT operations. But, total bilirubin was almost similar to that of the controls in their study.

In accordance with the current work, it has been found that management with human therapeutic dose of NVP caused liver injury through out hours after the first dose and this persist up to 7 to 14 days.

There was no proof of subclinical hepatic injury on days 14 and 21, however, which meant that the body overcame the pathological process of subclinical hepatic injury caused by NVP over time (**Bekker et al., 2012**).

Study by **Wen et al. (2009)** revealed that CYP3A4 transformed NVP metabolically into quinone methidine, a toxic reactive

metabolite, and, to a smaller extent, CYP2D6, CYP2C19, and CYP2A6, this metabolite may prevent its development.

This may explain the hepatic injury improvement after 14 and 21 days of therapy in part (**Bekker et al., 2012**).

Elias and Bonsome (2017) found that treatment with doses (4, 8, 16, 32) mg/kg/day of NVP for 14 days observed dose-dependent increases in serum and liver levels of ALT, AST, and ALP in NVP treated juvenile albino rats.

As a consequence of cellular leakage and loss of functional integrity of the liver cell membrane, the observed rises in serum concentrations of AST, ALT, and ALP may be due to the release of these enzymes in to the blood.

In addition, the elevation of serum total bilirubin may be attributed to overproduction, impaired uptake, conjugation or excretion of unconjugated or conjugated bilirubin from hepatocytes to bile ducts caused by NVP (**Thapa and Walia, 2007**).

Partially in agreement with the present results, **Adaramoye et al. (2012)** noted that at NVP administration at 18 mg / kg body weight / day for 4 weeks did not result in any important ($p > 0.05$) variations in the ALT and AST and ALP serum concentrations of rats handled with NVP relative to controls. But, NVP considerably enhanced serum concentrations of ALT, AST, and complete bilirubin concentrations in rats at 36 mg / kg body weight / day for 4 weeks of intoxication ($p < 0.05$).

The current study reported no statistically significant difference between the four groups regarding mean values of urea and creatinine levels. Mean values of urea of -ve control, +ve control, NVP1 and NVP2 treated groups were 26.8, 27.6, 33.2 and 28.6 mg/dl respectively, and for creatinine levels were 0.48, 0.50, 0.62 and 0.72 mg/dl respectively.

These findings were in a harmony with **Adaramoye et al. (2012)** who

reported that administration of NVP did not significantly ($p > 0.05$) alter the mean values of urea and creatinine levels.

Increased serum urea and creatinine levels indicate impairment to kidney functions such as acute glomerulonephritis, nephrosclerosis and even tubular necrosis (**Jaramillo-Juarez et al., 2008**). Therefore, NVP did not interfere with the animals' renal functions at the two doses administered. These results were supported by the histopathological changes of the slides taken from kidneys of the animals.

The present work showed a highly significant decrease in mean values of FSH, LH and testosterone levels in NVP1 and NVP2 treated groups as compared to the control groups. There is no statistical significant difference between the control groups; Also, there is no statistical significant difference between the treated groups.

The current findings were also in a harmony with those of **Awodele et al. (2018)** who found significant ($p < 0.05$) reductions in the blood levels of the hormones measured (LH, FSH and testosterone) in the treated group with NVP when compared to the control indicating a significant reduction in reproductive competency and point to a possible and potentially damaging adverse effect of NVP.

Decreased serum FSH, LH and testosterone levels indicated that male reproductive toxicity induced by NVP as well as a decreased function of Sertoli cell, in addition to the direct cytotoxic effects on germ cells.

The histopathological changes of the liver specimens of the loading dose treated group (NVP1) were including central vein congestion, fatty degenerations with singet ring appearance, hydropic degeneration.

Also, treated maintenance dose group (NVP2) showed changes in liver histopathology as severe portal and central

venous congestion and major distortion of architecture with marked necrosis.

These findings are consistent with **Elias and Bonsome (2017)**; **Olapido et al. (2015)** and **Adaramoye et al. (2012)** who discovered that NVP administration caused histopathological modifications in liver specimens including disorganized cytoarchitecture with sinusoidal and primary endothelial desquamation, mild portal vein congestion, and mild haemorrhage focal region. And when increasing the dose of nevirapine led to bad liver architecture, vascular congestion was observed; concentration of granuloma within the parenchyma of the liver was seen.

The present research did not show any histopathological modifications in the NV P1 and NVP2 handled rats kidney samples. No noticeable lesion in the tubular lumen, no tubular necrosis and no protein casts, and no interstitial hemorrhage.

These findings were in a harmony with **Adaramoye et al. (2012)** who reported that administration of NVP at 18 and 36 mg/kg body weight/day for 4 weeks resulted in no histopathological change in kidney.

In contrast, **Offor et al. (2017)** reported that there were extensive necrosis and atrophy of Bowman's capsule in NVP treated group. This might be due to the different dose (1.54 mg/kg for 56 days) which used in their study.

With respect to histopathological modifications in the current research, microscopic examination of male rat testicular samples disclosed seminiferous tubules (ST), spermatocyte necrosis, and defoliation of many spermatocytes into ST lumen. The changes were mild in loading dose treated group and more extensive in maintenance dose treated group.

The findings of this research coincided with those of **Ajayi et al. (2016)** and **Azu et al. (2014)** who reported that NVP administration revealed atrophy of the few spermatocytes discovered in the lumen of the seminiferous tubules, seminiferous tubules of lumen obliteration and atrophied tubules

were also observed in the test interstitial spaces.

The cause of these modifications may be due to nevirapine crossing the blood testis barrier by entering the junctional cell complexes, affecting the tubular microenvironment and causing death of germ cells (Meistrich et al., 1982).

Adaramoye et al. (2012) were partially agreed with the present work and reported that administration of NVP at 18 and 36 mg/kg body weight/day for 4 weeks resulted in testicular histopathological changes including normal architecture, mild necrosis with 18 mg/kg dose; major distortion, extensive degeneration of ST and severe necrosis of spermatocytes 36 mg/kg dose.

The current study showed that a highly significant increase in mean values of comet%, tail length, DNA % of tail and tail moment in NVP₁ and NVP₂ treated groups as compared to the control groups. There is no statistical significant between the control groups and no statistical significant between both treated groups.

Although de Oliveira et al. (2014) observed that the group treated with acute NVP (3.3 mg/kg single dose in 24 hours) and the subchronic treated group (3.3 mg/kg once daily for 36 consecutive days) did not show significant levels of genotoxicity or mutagenicity by using comet assay compared to the control group.

This controversy might be due to difference at the used dosage between the two studies. So, the genotoxic effect of NVP needs induction of more studies to ensure it on human.

CONCLUSION

In conclusion, this study observed that oral NVP administration at human loading and maintenance doses in rats (3.6 mg/200g, 7.2 mg/200g) respectively produced biochemical changes on liver functions of male adult albino rats. These biochemical changes were associated with

histopathological effects on their livers. Also, the same doses of NVP produced hormonal disruption effects in male rats. These disrupted effects were associated with histopathological damaging effects on testes. But, NVP did not disrupt renal histo-architecture or biochemical functioning of kidney. On the other hand, this current study demonstrated that human therapeutic dose of NVP induced genotoxic effects on whole blood cells of albino rats.

RECOMMENDATIONS

From the results of the present study, it can be recommended that:

1. Nevirapine should be used with caution and close tracking of liver enzymes as this can be critical in stopping incidents that threaten life.
2. Further clinical studies on the HIV infected individuals to assess the extent of genotoxic effects induced by the drug on blood and various organs of the body.
3. No countries should be using NVP-based regimens.

REFERENCES

- Adaramoye O, Adesanoye O, Adewumi O and Akanni O (2012): Studies on the toxicological effect of nevirapine, an antiretroviral drug, on the liver, kidney and testis of male Wistar rats. *Hum Exp Toxicol*, 31(7): 676–685.
- Adaramoye OA, Akanni OO and Farombi EO (2013): Nevirapine induces testicular toxicity in Wistar rats: reversal effect of kolaviron (biflavonoid from *Garcinia kola* seeds). *J Basic Clin Physiol Pharmacol*, 24(4): 313–20.
- Ajayi SA, Azu OO, Chaturgoon A, Phulukdaree A, Komolafe OA and Ofusori DA (2016): Comparison of Antioxidant Effects of Kolaviron and Vitamin C Interventions on Testicular Structures Following Nevirapine Administration in Sprague-Dawley Rats. *Int J Morphol*, 34(1): 102–109.

- Awodele O, Popoola TD, Idowu O, Bashua BM, Awolola NA and Okunowo WO (2018):** Investigations into the Risk of Reproductive Toxicity Following Exposure to Highly Active Anti-Retroviral Drugs in Rodents. *Tokai J Exp Clin Med*, 43(2):54–63.
- Banda J, Mweemba A, Siziya S, Mweene M, Andrews B and Lakhi S (2010):** Prevalence and Factors Associated with Renal Dysfunction in HIV Positive and Negative Adults at the University Teaching Hospital, in Lusaka. *Med J Zambia*, 37(3): 136-142.
- Bekker Z, Walubo A and du Plessis JB (2012):** The role of the immune system in nevirapine-induced subclinical liver injury of a rat model. *ISRN Pharmaceutics*, ID 932542.
- Bieniczak A, Cook A, Wiesner L, Mulenga V, Kityo C, Kekitiinwa A, et al. (2017):** Effect of diurnal variation, CYP2B6 genotype and age on the pharmacokinetics of nevirapine in African children. *J Antimicrob Chemother*, 72(1): 190-199.
- Biswas NM, Sen Gupta R, Chatopadhyay GR, Choudhury G R and Sarkar M (2001):** Effect of atenolol on cadmium-induced testicular toxicity in male rats. *Reprod Toxicol*, 15(6): 699-704.
- Colic A, Alessandrini M and Pepper MS (2015):** Pharmacogenetics of CYP2B6, CYP2A6 and UGT2B7 in HIV treatment in African populations: focus on efavirenz and nevirapine. *Drug Metab Rev*, 47(2): 111-23.
- Cabello A, Casas J, López JA, Delgado RG, Guerrero MLF, Górgolas M. (2015):** AIDS & Clinical Research Long-Term Efficacy of Nevirapine Plus Co-Formulated Abacavir /
- Azu OO, Naidu EC, Naidu JS, Masia T, Nzemande NF, Chaturgoon A and Singh S (2014):** Testicular histomorphologic and stereological alterations following short-term treatment with highly active antiretroviral drugs (HAART) in an experimental animal model. *Andrology*, 2(5): 772 - 9.
- Lamividune as Simplification Therapy in HIV-Infected Patients with Undetectable Viral Load. Journal of AIDS & Clinical Research, 6(5).**
- Cortez, JM, Quintero R, Moss JA, Beliveau M, Smith TJ and Baum MM (2014):** Pharmacokinetics of Injectable, Long-Acting Nevirapine for HIV Prophylaxis in Breastfeeding Infants. *Antimicrob Agents Chemother*, 59(1), 59–66.
- de Maat MM, ter Heine R, van Gorp EC, Mulder JW, Mairuhu AT and Beijnen JH (2003):** Case series of acute hepatitis in an unselected group of HIV-infected patients on nevirapine-containing antiretroviral treatment. *AIDS*, 17(15): 2209-14.
- de Oliveira HM, Damiani AP, Dias R de O, Romão PRT and Andrade VM (2014):** Effect of antiretroviral drugs on the DNA damage in mice. *Environ Toxicol Pharmacol*, 37(1): 390–5.
- Dhawan A, Bajpayee M, Pandey AK and Parmar D (2003):** Protocol for the single cell gel electrophoresis/comet assay for rapid genotoxicity assessment. Lucknow, India: Industrial Toxicology Research Centre, pp.1–10. Available from: <http://www.cometassayindia.org/protocolforcometassay.pdf>.
- Elias Adikwu and BonsomeBokolo (2017):** Possible hepatotoxic consequence of nevirapine use in juvenile albino rats. *Journal of*

- Pharmacy & Pharmacognosy Research; 5 (4): 217 - 226.
- Greenberg RS, Daniels RS, Flanders WD, Eley JW and Boring JR (1996):** Diagnostic testing. In: Medical epidemiology. 3rd ed., McGraw-Hill, New York, NY, pp: 77 - 89.
- Hall DB and Macgregor TR (2007):** Case-control exploration of relationships between early rash or liver toxicity and plasma concentrations of nevirapine and primary metabolites. *HIV Clin Trials*, 8 (6): 391– 399.
- Jaramillo-Juarez F, Rodriquez-Vazquez ML, Rincon- Sanchez AR, et al. (2008):** Acute renal failure induced by carbon tetrachloride in rats with hepatic cirrhosis. *Ann Hepatol*, 7(4):331-8.
- Khothari CR(2004):** Research Methodology: Methods and Techniques, New Age International, New Delhi.
- Końca K, Lankoff A, Banasik A, et al. (2003):** A cross-platform public domain PC image-analysis program for the comet assay. *Mutat Res*, 534(1–2):15–20.
- Kushnir VA and Lewis W (2011):** Human immunodeficiency virus/acquired immunodeficiency syndrome and infertility: emerging problems in the era of highly active antiretrovirals. *FertilSteril*, 96(3): 546-53.
- Litud SOL, Externa DER, Externa SDER, Carlos J, Nebot P, Del NOM, et al. (2015):** Annex I. 2015;1999.
- Lockman S, Shapiro RL, Smeaton LM, et al. (2007):** Response to antiretroviral therapy after single, peripartum dose of nevirapine. *N. Engl. J. Med*, 356(2): 135-47.
- Hall AP, Elcombe CR, Foster JR, Harada T, Kaufmann W, Knippel A, et al. (2012):** Liver hypertrophy: A review of adaptive (adverse and non-adverse) changes-conclusions from the 3rd international ESTP expert workshop. *ToxicolPathol*, 40(7): 971–94.
- Makori JO, Osanjo GO, Oluca MN, et al. (2015):** Incidence and Risk Factors of Renal Dysfunction in Patients on Nevirapine-Based Regimens at a Referral Hospital in Kenya. *Afr J PharmacolTher*, 4 (2): 48-58.
- Manosuthi W, Mankatitham W, Lueangniyomkul A, et al. (2010):** Renal impairment after switching from stavudine / lamivudine to tenofovir / lamivudine in NNRTI-based antiretroviral regimens. *AIDS Res Ther*, 7: 37.
- Meistrich ML, Finch M, Cunha MF, Hacker U and Au WW(1982):** Damaging effects of fourteen chemotherapeutic drugs on mouse testis cells. *Cancer Res*, 42(1):122-31.
- Mohamed Saleem TS, Jyothi K and Babu SC (2019):** Report: A case report on Nevirapine induced exfoliative dermatitis. *Pak J Pharm Sci*, 32(1):221-222.
- Offor U, Ajayi SA, Jegede IA, Kharwa S, Naidu EC and Azu, O (2017):** Renal histoarchitectural changes in nevirapine therapy: possible role of kolaviron and vitamin C in an experimental animal model. *Afr Health Sci*, 17(1):164-174.
- Oladipo EK, Afolabi AY, Oloke JK and Awoyelu EH (2015):** Histological and biochemical markers of the liver of

- male Wistar. *African Journal of Clinical and Experimental Microbiology*, 17(1): 53 – 61.
- Paget GE and Barnes JM (1964):** Toxicity tests in evaluation of drug activities pharmacometries (Laurence, D. R. and Bacharach, A. L. eds) Academic Press, London and New York.
- Rather ZA1, Chowta MN, Prakash Raju GJ and Mubeen F (2013):** Evaluation of the adverse reactions of antiretroviral drug regimens in a tertiary care hospital. *Indian J Pharmacol*, 45(2): 145-8.
- Riska PS, Joseph DP, Dinallo RM, Davidson WC, Keirns JJ and Hattox SE (1999):** Biotransformation of nevirapine, a non-nucleoside HIV-1 reverse transcriptase inhibitor, in mice, rats, rabbits, dogs, monkeys, and chimpanzees. *Drug MetabDispos*, 27(12):1434-47.
- Roca B (2009):** Adverse drug reactions to antiretroviral medication. *Front Biosci (Landmark Ed)*, 14:1785-92.
- Shenton JM, Popovic M, Chen J, Masson MJ and Uetrecht JP (2005):** Evidence of an Immune-Mediated Mechanism for an Idiosyncratic Nevirapine-Induced Reaction in the Female Brown Norway Rat. *Chem Res Toxicol*, 18(12):1799-813.
- Thapa BR and Walia A (2007):** Liver function tests and their interpretation. *Indian J Pediatr*, 74(7): 663–671.
- Umar RA, Hassan SW, Ladan MJ, Matazu IK, Shehu B, Shehu RA, Muhammed LG and Molabo FI (2008):** Adverse Hepatic Effects Associated with Administration of Antiretroviral Drugs (Nevirapine, Lamivudine and Stavudine) to Albino Rats: Implication for Management of Patients with HIV/AIDS. *Asian Journal of Biochemistry*, 3(1): 19-25.
- Usach I and Peris JE (2011):** Bioavailability of nevirapine in rats after oral and subcutaneous administration, in vivo absorption from gastrointestinal segments and effect of bile on its absorption from duodenum. *Int J Pharm*, 419(1-2): 186191.
- Wen B, Chen Y and Fitch WL (2009):** Metabolic activation of nevirapine in human liver microsomes: dehydrogenation and inactivation of cytochrome P450 3A4, *Drug MetabDispos*, 37(7): 1557 – 62.

الآثار السمية للدواء المضاد للفيروسات الرجعية (نيفيرابين) على ذكور الفئران البيضاء البالغة: دراسة وراثية وخلوية

*ياسمين بدرالدين عبدالمجيد، *أمينة عبدالمعطي فرج و *محمد أحمد الششتاوى

*قسم الطب الشرعى و السموم الأكلينيكية، كلية الطب البشري – جامعة بنها - مصر

الملخص العربي

النيفيرابين (NVP) هو أحد مثبطات النسخ العكسي الغير النوكليوزيدية المستخدمة في علاج عدوى الايدز. وقد تم الإقرار بأنه سام للكبد والكلى والجهاز التناسلي الذكري. ولقد صممت هذه الدراسة لتقييم التأثيرات السامة له على الأنسجة (الكبد والكلى والخصية) ولتقييم إمكانية تأثيره على الجينات وإحداث الطفرات. فُسمت 40 من الذكور البالغة للفئران البيضاء إلى 4 مجموعات (10 فئران لكل منها): (أ) مجموعة تحكم سالبة، (ب) مجموعة تحكم موجبة أخذت 1مجم/يومياً من زيت الذرة، (ج) مجموعة معالجة بالنيفيرابين أخذت 3.6 مجم (جرعة أولية) من الدواء لمدة أسبوعين و (د) مجموعة معالجة بالنيفيرابين أخذت جرعة أولية من الدواء لمدة أسبوعين ثم 7.2 مجم (جرعة مكملة) لمدة أسبوعين آخرين. وقد بينت نتائج الدراسة المجراة الآتي: لم يحدث للنيفيرابين تغيير في زيادة وزن الجسم ولا وزن الكلى ولكن كانت هناك زيادة في وزن الكبد في (المجموعة ج) وانخفاض في وزن الخصية في (المجموعة د). ولقد تسبب النيفيرابين في زيادة ملحوظة في تحاليل وظائف الكبد (الإنزيمات الناقلة للاسبرتات، والناقلة للألانين، والفوسفاتيز القلوي، والبيليروبين الكلي). وأيضاً أحدث انخفاض ملحوظ في مستويات هرمونات الخصية (التيستوستيرون و FSH و LH). ولم يسبب النيفيرابين أي تأثير على تحاليل وظائف الكلى (اليوريا والكرياتنين). ولوحظ تغيرات هستوباثولوجية في الكبد والخصى للمجموعات المعالجة بالنيفيرابين على عكس مجموعات التحكم. وقد أوضحت دراسة الكومت أن النيفيرابين تسبب في تدمير ملحوظ لخلايا الدم تناسباً مع الجرعة المأخوذة. هذه النتيجة تشير لأول مرة على أن هذا الدواء قد يؤدي إلى السمية الوراثية في الدم. وللتلخيص معالجة الذكور البالغة للفئران البيضاء بالادوية المحتواة على النيفيرابين عن طريق الفم بجرعة مساوية للجرعة العلاجية للإنسان يومياً لمدة 4 اسابيع تؤدي إلى تأثيرات سامة على الكبد وتأثير مدمر للجهاز التناسلي الذكري بالإضافة إلى التأثير السمي الجيني.